

# Gastrointestinal Intervention

journal homepage: [www.gi-intervention.org](http://www.gi-intervention.org)

## Review Article

## Endoscopic management of postsurgical leaks

Hany Shehab\*



### ABSTRACT

Postsurgical leaks are a major complication with significant morbidity and mortality. Conventional conservative and surgical approaches are highly morbid with limited success. Over the last decade several endoscopic techniques have proved effective with a favorable safety profile. Nevertheless, most data still come from retrospective series, and many studies included heterogenous patient groups pooling complex surgical leaks with minor endoscopic perforations. This review focuses on the endoscopic management of the more difficult postsurgical leaks. Stents and over-the-scope clips are currently the key endoscopic techniques for leak closure, but emerging techniques such as vacuum sponge therapy and endoscopic internal drainage have proved to be at least as effective. The current trend is to use these different techniques interchangeably or simultaneously rather than assuming a single standardized approach.

Copyright © 2016, Society of Gastrointestinal Intervention. All rights reserved.

**Keywords:** Anastomotic leak; Esophageal fistula; Gastric fistula; Over-the-scope clips; Self expandable metallic stents

### Introduction

A postsurgical gastrointestinal (GI) leak is one of the most dreaded surgical complications with significant morbidity and mortality.<sup>1–3</sup> Leakage of luminal contents leads to the formation of infected collections with rapid development of systemic sepsis. Those who survive the initial event may end up with chronic tenacious fistulas strongly compromising quality of life and associated with prolonged hospitalization. The incidence of postsurgical leaks varies widely in different reports depending on several factors; mainly type, location and indication of surgery and surgeon experience.<sup>2–6</sup> The reported incidence in upper GI surgeries is in the range of 4% to 17% with a mortality of about 10% to 65%.<sup>1,3,7</sup> The incidence in bariatric surgeries in particular may be lower (1% in sleeve gastrectomy and up to 5% in Roux-en-Y gastric bypass [RYGB]) but the number of bariatric surgeries being performed has been rising exponentially over the last two decades making bariatric surgeries a commonly encountered cause of leaks.<sup>2,4–6</sup> The risk of leakage after colorectal anastomoses is about 3% to 15% with a mortality of about 10%.<sup>8–10</sup> The mainstay of treatment for GI leaks used to depend on a choice between either conservative management or surgical repair, any experienced surgeon would know that this is being “caught between the devil and the deep blue sea”. Conservative management involves

prolonged total parenteral nutrition (TPN) and use of multiple antibiotics until spontaneous healing occurs. This approach entails prolonged hospitalization, recurrent infections, numerous complications of TPN and a low rate of success.<sup>7</sup> The option of surgical repair is also far from optimal, anatomy is markedly altered by the recent surgery, the developing adhesions and presence of pus, repair very frequently fails and leaks recur due to tissue friability and the presence of infection.<sup>11</sup> Morbidity is usually very high with mortalities up to 50%.<sup>12,13</sup> The exception to this of course is repair performed very early (few hours) after the leak occurs, a situation seldom encountered.

Over the last 2 decades endoscopic alternatives have surfaced as an exciting alternative in the management of leaks. The endoscopic approaches have the advantages of being minimally invasive, many are not affected by the condition of the leak edges and they reduce the need for prolonged parenteral nutrition and hospital stay. Studies on endoscopic approaches have generally reported favourable results, yet there is still a lack of large prospective and randomized studies. Another caveat in many of these studies is that they pooled perforations occurring iatrogenically during endoscopy with leaks occurring postsurgically. Iatrogenic endoscopic perforations have a much better prognosis mainly due to the very early diagnosis, many heal spontaneously, and the vast majority respond well to endoscopic intervention during the

Gastrointestinal Endoscopy Unit, Kasr Alainy University Hospital, Cairo University, Cairo, Egypt

Received September 1, 2015; Revised November 21, 2015; Accepted November 25, 2015

\* Corresponding author. Gastrointestinal Endoscopy Unit, Kasr Alainy University Hospital, Cairo University, Kasr Alainy Street, Cairo 11562, Egypt.

E-mail address: [h.shehab@kasralainy.edu.eg](mailto:h.shehab@kasralainy.edu.eg) (H. Shehab).

pISSN 2213-1795 eISSN 2213-1809 <http://dx.doi.org/10.18528/gii150023>

© This is an open-access article distributed under the terms of the Creative Commons Attribution Non-Commercial License (<http://creativecommons.org/licenses/by-nc/3.0>) which permits unrestricted noncommercial use, distribution, and reproduction in any medium, provided the original work is properly cited.

same endoscopic session. For the purpose of this review we will be discussing only the management of the more tenacious postsurgical leaks.

## Fundamentals of Endoscopic Leak Management

A patient with a leak is not the patient that will just be done within your routine endoscopy list, nor is there a routine approach that will be applied to all patients with leaks. It is vital for an endoscopist approaching such a case to understand that there is more to it than just “plugging the hole”, what is more important is maintaining this closure. This depends on several factors which necessitate a wider angle view of the patient, an understanding of some basic surgical principles and a very tight collaboration with the managing team. It is beyond the scope of this article to list all principles of leak management, but below are a few main principles that may be frequently overlooked by endoscopists.

### Drainage

This may go without saying for most surgeons but it may be a principle long forgotten by many endoscopists. Drainage is arguably the single most important step in the management of a GI leak. The first question on the endoscopist's checklist should be: are all the collections well-drained? Without proper drainage sepsis is inevitable, apart from being life threatening, it renders the patient in a poor general status impairing the healing process, and without proper drainage the formed pus will be continuously damaging the leakage site precluding any chance of healing. Inserting a stent blocking the leak site with no drains inserted could just block the only possible exit of the collected pus, seriously aggravating the infection process. Options of drainage include ultrasound- or computed tomography-guided drainage or surgical drainage. Drains should be inserted close to the leakage site and in any other collections even if apparently remote. Drains inserted too close have the risk of migrating into the lumen through the leak, or impairing healing due to their continuous vacuum effect. Repeated contrast studies and the gradual withdrawal of the drains prevent this complication from occurring.

Drainage can also be performed endoscopically. In cases with large leaks the endoscope can be passed through the leak into the surrounding collections. All fluids can be aspirated, and more importantly, necrotic debris, solid material and foreign bodies such as sutures can be extracted. Passing the endoscope through the leak used to be considered an absolute “faux pas”, but now I believe it should be considered an opportunity not to be missed. The aspiration and cleansing of the leak cavities by the endoscope is much more comprehensive and effective than radiologic-guided drainage and much less invasive than surgical drainage.

### Endoscopy unit setting

I find it essential to perform all procedures with fluoroscopic guidance. Although theoretically possible, performing such procedures with only an endoscopic view severely narrows the assessment of the leak and its extent and does not allow confirmation of technique success. Another vital issue in the setting is the availability of different endoscopic solutions for leak closure as it is almost impossible to decide on which technique will be used prior to performing the endoscopy. The endoscopist has to know that these patients may only have one chance to undergo the endoscopic procedure, compromising this chance by using suboptimal equipment might actually make things worse for the patient.

A proper inventory would include at least: Fully covered stents with lengths between 12 to 23 cm and diameters between 20 to 28 mm, flexible and rigid guidewires, through-the-scope (TTS) clips, over-the-scope (OTSC) clips of variable diameters, fibrin glue, histoacryl, balloon dilators 12 to 20 mm, cytology brushes, endoscopic scissors and an argon plasma coagulation (APC) unit. Availability of a small calibre (pediatric) endoscope is very useful in situations needing tight angulation or when passing through a small leak is necessary to aspirate collections. Double channel endoscopes with wide channels are also valuable in the presence of thick pus/necrotic tissue and the need for strong suction while using the instrument channel.

### Expertise

Endoscopic management of GI leaks is highly demanding technically, but more importantly is the necessary expertise of managing these cases as a whole: decision making such as to intervene or not, when to intervene, choice of endoscopic methods, assessment of radiologic findings before and after endoscopic procedures, detailed knowledge of different post-surgical anatomies etc. Unless the endoscopist is actually a surgeon, the optimal situation is having a “hybrid” endoscopist/surgeon which can merge the different views and knowledge of each. This requires dedication and following a rather long learning curve. For example I have found it extremely useful as an endoscopist to actually attend surgeries performed to drain patients with leaks. To be able to *feel* the friable tissue at the leak site, to *feel* the texture and consistency of an eroding band and thus knowing how to cut it endoscopically, to see the nature and extent of damage on the outside of the leak in the peritoneal cavity, have all drastically changed my assessment and understanding of leaks and their management.

### Multidisciplinary approach

A team managing such cases should comprise at least: a surgeon experienced in managing GI leaks, the operating surgeon (his knowledge of what actually happened during the surgery could be invaluable to the endoscopist), a dedicated endoscopist, an intensivist, a nutritionist and an experienced radiologist. Psychiatric help is also frequently necessary as many of these patients suffer depression which may be severe, nutritional deficiencies may also be associated with neurological and psychiatric disturbances. A tight collaboration between all team members is vital, it is really hard to point out which one is more important for the survival of the patient.

### Confirmation of leak closure

A normal oral contrast study is not sufficient evidence of an adequate sealing of the leak whether by a stent, clip or any other technique. It is the composite result of drain output, clinical status and contrast studies that leads to this conclusion. Therefore, surgical drains should be removed only after at least a week of normalization of all these parameters.

### De-epithelialization

One of the main obstacles to leak healing is epithelialization of the leak site and tract. This occurs in chronic fistulas and can render any endoscopic therapy futile. De-epithelialization or “roughening” of the leak edges can be achieved by a cytology

brush, standard biopsies or forceps, but our preferred method is APC. APC at low settings (30 W) can be easily applied to the leak edges and the tract walls.<sup>14,15</sup> Care should be taken because a large part of these tracts are composed of thin granulation tissue. In our practice we routinely de-epithelialize any leaks older than 2 weeks.

### Antibiotics

Once a leak is suspected an aggressive approach including multiple antibiotics is essential. Our empirical regimen includes intravenous amikacin, vancomycin, and clindamycin, which is then changed according to culture results. We recommend the continuation of antibiotics for at least 2 weeks after presumed leak closure (cessation of fever and drain output and normalization infection markers such as C-reactive protein and leucocytic count). Leaks are associated with prolonged use of multiple antibiotics and a poor nutritional status, the perfect conditions for fungal infection. In our practice an antifungal (fluconazole) is empirically administered in patients receiving antibiotics for over 10 days especially if markers of infection do not completely resolve.

### Endoscopic Techniques for Leak Closure

#### Stents

The purpose of stenting is to divert the route of alimentation, saliva and gastric/intestinal secretions away from the site of leak thus preventing infection and creating a more stable environment for tissue healing. Initially most studies addressed the use of self-expandable plastic stents (SEPS), but these stents had a high rate of migration (up to 50%), an arguably cumbersome assembly technique and a large calibre delivery system.<sup>16–18</sup> Recently self-

expandable metallic stents (SEMS) have become the first choice in the treatment of leaks. Uncovered metallic stents are not used as tissue hyperplasia develops rapidly and the stent becomes embedded within the mucosa rendering it unextractable. Partially covered SEMS (PCSEMS) have a small uncovered segment (about 1–2 cm in length) which renders them less liable to migration, but this segment can also become completely embedded within the hyperplastic mucosal tissue rendering stent extraction very difficult if at all possible. Fully covered SEMS (FCSEMS) are currently the preferred option by many experts as their extraction is simple, but this comes at the expense of a higher rate of migration.<sup>17</sup> In a pooled analysis by van Halsema and van Hooft<sup>19</sup> the migration rate was 21.8% (53/243) and 10.6% (23/218) for FCSEMS and PCSEMS, respectively.

Stents are probably the most studied endoscopic technique in leak management and currently have the most robust evidence of efficacy. However, most studies have pooled results of post-surgical leaks and perforations despite their different nature, many have also pooled different stents together.<sup>20–23</sup> The largest and most recent studies including only post-surgical leaks or providing subgroup analysis of post-surgical leaks are listed in Table 1.<sup>18,23–27</sup> These studies show a pooled success rate of 76%, a very encouraging result putting in consideration the low rate of serious adverse events, and a great improvement in comparison to conventional non-endoscopic approaches. It is to be noted though that many of these patients eventually healed after the insertion of several stents, thus the failure of healing after removing the first stent should not be considered an endoscopic failure, further attempts should be sought unless there is frank deterioration of the patient's general condition and need for urgent surgical intervention.

Factors associated with non-healing seem to be a larger leak size and delayed endoscopic intervention.<sup>24,28</sup> In the study by

**Table 1** Recent Large Studies on Stents for the Management of Postoperative Leaks

| Study                                      | Total patients (n) | Patients with postsurgical leaks (n) | Indication  | Stent type                   | Stent name                              | Mean time to stenting (day) | Migration (%)     | Major adverse events, % (n) | Stents per patient | Success after single stent, % (n) | Overall success, % (n) |
|--|--------------------|--------------------------------------|---|------------------------------|---|-----------------------------|-------------------|-----------------------------|--------------------|-----------------------------------|------------------------|
| Dai et al <sup>18</sup> (2011)             | 41                 | 30                                   | Esophageal anastomotic leaks                                    | SEPS                         | Polyflex                                | 2.7                         | 34                | 3.3 (1/30) <sup>‡</sup>     | NA                 | NA                                | 90.0 (27/30)           |
| Feith et al <sup>23</sup> (2011)           | 115                | 115                                  | Esophageal anastomotic leaks                                    | FCSEMS                       | Choo stent, Niti-S stent                | 8                           | 53                | 3.5 (4/115) <sup>§</sup>    | NA                 | 51.3 (59/115)                     | 69.6 (80/115)          |
| Leenders et al <sup>27</sup> (2013)        | 26                 | 26                                   | Leaks after: esophageal resections, bariatric surgeries         | FCSEMS 24, PCSEMS 2          | Choo, Hanaro, Endoflex                  | 7.9                         | 24.2 <sup>‡</sup> | 3.8 (1/26) <sup>  </sup>    | 1.3                | NA                                | 80.8 (21/26)           |
| Orive-Calzada et al <sup>26</sup> (2014)   | 56                 | 46                                   | Leaks after: esophageal resections, bariatric surgeries, Nissen | FCSEMS 45, PCSEMS 1          | Hanaro                                  | 23.5                        | 67.8              | 5.4 (3/56) <sup>  </sup>    | 1.6                | NA                                | 78.3 (36/46)           |
| Gubler and Bauerfeind <sup>25</sup> (2014) | 85                 | 31                                   | Esophageal anastomotic leaks                                    | FCSEMS, PCSEMS*              | Ultraflex, Hanaro, Niti-S, Rusch        | 17                          | 8.8 <sup>‡</sup>  | 6.5 (2/31) <sup>¶</sup>     | 1.3                | NA                                | 74.2 (23/31)           |
| El Hajj et al <sup>24</sup> (2014)         | 54                 | 29                                   | Esophageal anastomotic leaks                                    | FCSEMS 42, PCSEMS 7, SEPS 15 | Alimax-E, Wallflex, Ultraflex, Polyflex | 14                          | 28                | 7.4 (4/54)**                | 1.9                | 72.4 (21/29)                      | 82.8 (24/29)           |
| Pooled result                              |                    |                                      |   |                              |   |                             |                   |                             |                    |                                   | 76.2 (211/277)         |

SEPS, self-expandable plastic stents; FCSEMS, fully covered SEMS; PCSEMS, partially covered SEMS; NA, not available.

\*Numbers of each not available.

<sup>‡</sup>Migration rate per stent not per patient.

<sup>§</sup>Stent dislocation requiring rethoracotomy.

<sup>||</sup>Perforation (1/115), intestinal obstruction (3/115), irremovable stent (2/115).

<sup>¶</sup>Perforation.

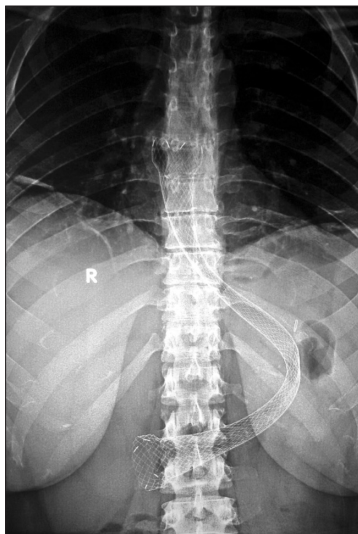
<sup>\*\*</sup>Irremovable stents.

\*\*Analysis includes all patients in study, no subgroup analysis of adverse events in surgical leaks group. In one patient each: widening of leak on deployment, bleeding, pneumothorax, stent fracture.

El Hajj et al,<sup>24</sup> 54 patients who underwent stent therapy were grouped into responders (40 patients) and non-responders (14 patients). Responders had a significantly shorter delay to endoscopic intervention than non-responders (9 vs 23 days;  $P = 0.003$ ). A smaller leak size in responders was the only other significant difference between the 2 groups.<sup>24</sup> Similarly, the study by Bège et al<sup>28</sup> included 27 patients with post-bariatric surgery leaks who underwent stent therapy, the group who had earlier endoscopic intervention ( $< 30$  days from time of diagnosis,  $n = 13$ ) healed in a significantly shorter time (95 vs 210 days;  $P = 0.005$ ) and required fewer endoscopic sessions (average of 3.15 vs 5.57 sessions) than the group presenting  $> 30$  days after diagnosis of leakage ( $n = 14$ ).<sup>28</sup> Surgeons used to be (and many still are) sceptical about early endoscopic interventions. This is partly due to the fear of damage to fragile staple lines by endoscopic manoeuvres or insufflation. There is also always this hope that the leak would heal spontaneously with watchful waiting. It is now obvious that the risks of early endoscopic intervention are minimal, especially in expert hands and with the use of CO<sub>2</sub> insufflation. Several experts now opt for an early endoscopy as the first step when a leak is suspected even before confirmation by contrast studies.<sup>23</sup>

Bariatric surgery leaks in particular seem to respond well to stent therapy. A systematic review by Puli et al<sup>29</sup> included 67 patients diagnosed with post-bariatric surgery leaks who underwent treatment by expandable stents (plastic and metallic). The success rate was 88% with a migration rate of 17%. Some stents have been designed with specifications tailored to bariatric surgery leaks such as the ultra-long, wide and flexible Mega stent (Taewoong Medical, Gimpo, Korea) for sleeve gastrectomy (Fig. 1) and the segmented Beta stent for RYGB (Taewoong Medical). So far no large trials have confirmed superiority of these stents to conventional ones.

No consensus is yet present for the duration of stenting. In the study by van Heel et al<sup>30</sup> extraction of all stents within 6 weeks of insertion was successful without complications while 50% of those with an indwelling time of 6 to 84 weeks had major complications such as bleeding and stent fracture. Most experts agree that 6 weeks is usually appropriate. Shorter periods may be sufficient for small non-infected leaks.



**Fig. 1.** A 23-cm Mega stent (Taewoong Medical) inserted in a patient with a leak after sleeve gastrectomy. Note the flexibility of the stent as the lumen does not kink despite the tightness and acute angulation of the gastric sleeve.

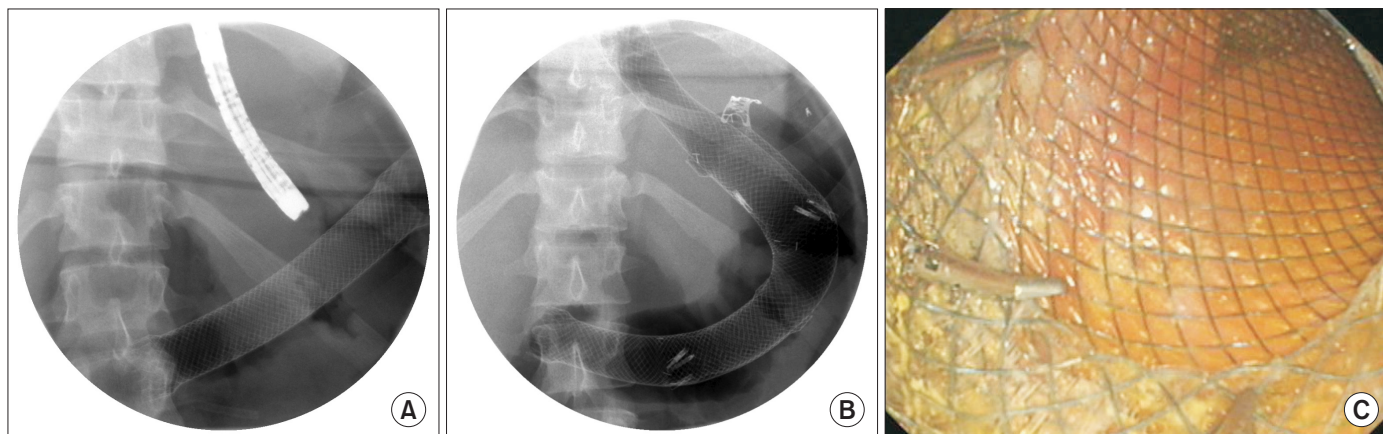
The Achilles tendon of stents is the high rate of migration, studies assessing FCSEMS report migration in 20% to 84%, with the largest series reporting 53%.<sup>18,23,25–28,31–33</sup> Migration necessitates re-intervention for stent positioning or exchange, and may be associated with serious adverse events such as perforation or necessity for surgical extraction.<sup>23,25,26</sup> Many attempts have been made to overcome this problem. The use of PCSEMS and a “stent-in-stent technique” for extraction has been proposed by some authors.<sup>34</sup> The technique entails the insertion of a PCSEMS, and after 4 to 6 weeks a FCSEMS or SEPS of the same size and length is inserted inside the older one for a week. The second stent compresses against the hyperplastic tissue causing pressure necrosis, both stents are then extracted together in a third session. In their experience of 76 patients, Swinnen et al<sup>34</sup> reported a healing rate of 84%, migration occurred in 11%, and failure to extract the stents occurred in 4% of patients. The results are tempting but caveats still exist with this technique; firstly, the technique by default adds a second stent and a third endoscopic procedure (for insertion of the SEPS inside the first stent), adding to the costs and risks. Secondly, tissue hyperplasia inside the PCSEMS is associated with luminal obstruction and significant dysphagia necessitating repeated dilatations or insertion of other stents in about 20% of cases. Thirdly, failures do still occur even after inserting a stent inside a stent, resulting in an irremovable stent necessitating a highly morbid surgical extraction. Some endoscopists attempted using TTS clips to attach the upper edge of the stent to the luminal wall, this technique has been repeatedly shown to be ineffective.<sup>28,35,36</sup> Stent modifications have been also attempted with data still lacking to confirm their effectiveness. The Choo stent (M.I. Tech, Seoul, Korea) has a proximal lasso that is brought out of the nostril and looped around the ear lobe thus preventing migration. The recently developed Mega stents (Taewoong Medical) have an ultra large diameter (28 mm shaft, 36 mm flared end) and significantly more flexibility thus proposedly reducing migration. Another technique that we have developed is the use of overlapping “stapled” stents. In this technique the migrated stent is left just a few centimetres below the leak and another stent is inserted inside the migrating stent in an overlapping manner with the upper edge lying above the leak site. The 2 stents are then fixed in this position by 3 endoscopic clips fixing the lower edge of the new stent to the shaft of the migrated stent (Fig. 2), this allows reaching stent lengths not attainable by any available stent. We have used this technique so far in 3 patients with gastroesophageal junction leaks, all were successful.

Complications have been reported with the use of stents including perforation, stricture formation, intolerance, bleeding and tracheal compression.<sup>19</sup> The risk of serious adverse events is low but significant (3%–7%), requiring vigilance throughout the period of stenting, repeated contrast studies and frequent clinical assessments.<sup>19,23–28</sup> With the exception of long stent indwelling time ( $> 6$  weeks), no analysis so far has deduced other risk factors associated with the occurrence of complications.


### Endoscopic clips

TTS clips have been greatly successful in the management of GI bleeding. Many earlier reports have initially shown successful use of clips in sealing post-surgical leaks.<sup>37–39</sup> These reports, however, were mostly case reports or very small case series and were probably strongly affected by publication selection bias. TTS clips are hampered by their weak superficial grasp attaching only to the mucosal layer, thus not providing sufficient tissue apposition. These clips also need sufficient space for deployment, a condition





**Fig. 2.** (A) Migrated stent lying horizontally in stomach. (B) An over-the-scope clip is applied to seal the gastroesophageal junction leak (upper right corner), two additional overlapping stents are inserted to ensure stent coverage from esophagus to duodenum and fixed together by through-the-scope clips. (C) Three through-the-scope clips fixing the overlapping stents together.



**Fig. 3.** The over-the-scope system (Ovesco). (A) Variable sizes and configurations of the over-the-scope clips, those with blunt teeth are preferred in bleeding and in thin structures such as esophagus and proximal colon while sharp ones are preferred in the stomach. (B) A loaded over-the-scope clip and an open tissue anchor.

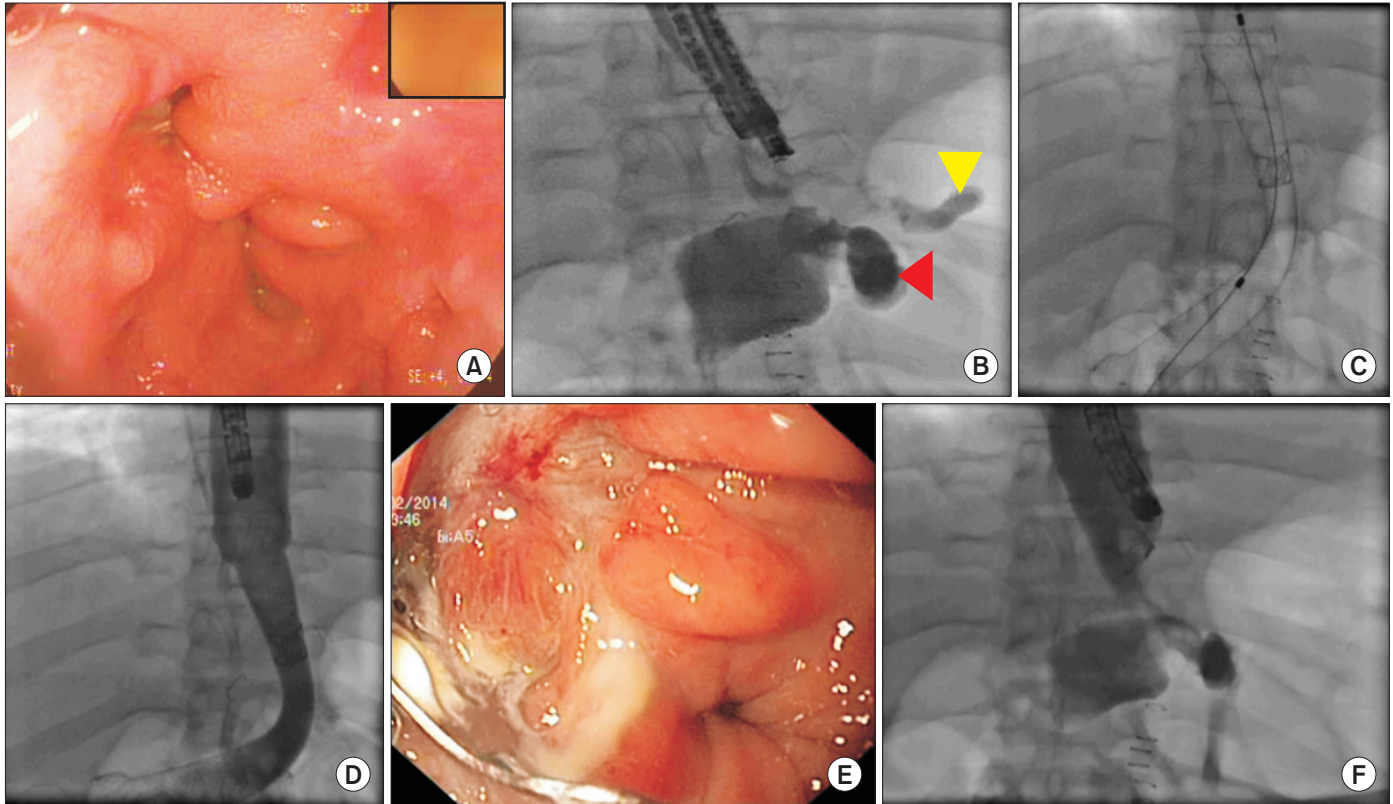
seldom present at anastomotic sites in the immediate post-operative period. Recently, the OTSC clip has been developed (Ovesco, Tubingen, Germany) providing a clip that has a strong grasp including more than the mucosal layer (Fig. 3). The OTSC is made of super-elastic nitinol, it is loaded over a cap and deployed in a fashion similar to that of endoscopic bands. The tissue around the leak is drawn into the cap by suction and then the clip is released. Two accessories are available to help draw more tissue into the cap: the tissue anchor and the twin-grasper (Ovesco). Apart from being large in diameter, the elastic nature of the OTSC means that there is continuous pressure on the grasped tissue, so even when edema resolves and the grasped tissue shrinks, sufficient pressure will still be present to maintain tissue apposition.

After a few initial small case series, recently larger studies have emerged all reporting encouraging results, however, all still retrospective in nature.<sup>40–42</sup> Haito-Chavez et al<sup>43</sup> recently reported the largest series of postoperative leaks treated by OTSC clips, their study included 32 patients, 15 patients (47%) presenting after colorectal surgery and 17 patients (53%) after upper GI surgeries. One clip was used in 25 patients while 2 clips were used in 2 patients. Technical success was achieved in 90% of patients while long-term healing occurred in 22 patients (73%).<sup>43</sup> Mercky et al<sup>44</sup> reported their similar experience with OTSC in 30 patients, 27 patients of which had postsurgical leaks while 2 patients were post-mucosectomy and 1 patient had a Crohn's rectovaginal fistula. Technical success was eventually achieved in all cases (4 patients needed 2 attempts). Successful healing after the first attempt alone occurred in 53% (16/30) while eventual overall success (after additional endoscopic techniques) was 70% (21/30).<sup>44</sup>

### Stents vs clips?

In the study by Farnik et al,<sup>45</sup> the authors performed a retrospective comparison of OTSC and stents in the management of leaks and perforations. In the postoperative leaks subgroup OTSC's were successful in 56% (9/16) in comparison to 39% (22/57) in patients treated with stents. Post-interventional leaks (endoscopic perforations) healed significantly better (OTSC 87% [13/15], stents 44% [4/9]). The authors, however, reasonably did not conclude the superiority of OTSC's to stents. They found that patients in the stent group had significantly larger leaks (12.6 vs 7.1 mm), more frequently had local abscesses (71% vs 44%) and had a significantly longer intensive care unit stay (7 vs 0 days).<sup>45</sup> I highly concur with the authors' conclusion that the two techniques are complementary rather than competing, patients with larger leaks or evidence of infection may benefit better with stents, while OTSC's might be considered as a first choice in those with smaller non-infected leaks and a favourable position for clip application.

At our institution we have adopted a strategy for bariatric surgery leaks in particular favouring the combination of the 2 techniques whenever possible. When approaching a postoperative leak we believe the optimal situation would be a applying a clip to seal the leak and simultaneously inserting a stent (Fig. 4). The stent offers 3 main advantages: firstly, provides additional sealing to the leak site thus promoting healing while allowing early enteral nutrition. Secondly, it eliminates any distal stenosis to the leak, whether a frank stricture or subtle stenosis (as in sleeve gastrectomies). This distal stenosis leads to a reservoir effect at the site of leakage impairing its healing. Thirdly, presence of the



**Fig. 4.** (A) Leak just above the gastroesophageal junction after sleeve gastrectomy. (B) Leak into left subphrenic space (white arrow), note the markedly twisted gastric sleeve causing relative obstruction distal to the leak (black arrow). (C) Over-the-scope clip applied and a 23-cm fully covered self-expandable metallic stent deployed. (D) Contrast injection confirms no further leakage. (E, F) Four weeks later, clip well embedded in the wall, no further leakage.

stent will reduce the risk of development of stenosis at the site of leakage, a common complication occurring after leak healing. Applying a clip, however, should not be attempted if there is any evidence of infection or if the leak is not in a favourable position for clip application (tangential or requiring acute retroflexion of endoscope). So in our practice a stent may be inserted alone but application of a clip alone is much less common, only in cases where stent application is not suitable (e.g., colonic leaks) and under the condition of healthy leak walls and absence of any evidence of infection. These conditions are seldom present in post-operative leaks but typical of post-endoscopic perforations. Our recently published series included 22 patients with post-bariatric surgery leaks treated with Mega stents with or without OTSC clips. Our algorithm includes putting a stent in all patients in the first session with or without an OTSC sealing of the leak, in further sessions however clips are favoured as infection has resolved and tissues are less friable. Clips were applied in 12 patients (55%); 5 simultaneously with stents and 7 after stent removal. An average of 1.4 stents and 2.8 endoscopic procedures were required per patient. Primary success after 1 endoscopic procedure occurred in 59% while long-term success was achieved in 18 patients (82%). Of the 4 failures 2 had persistent leaks only detected radiologically but with no symptoms or clinical sequelae, including those would raise the success rate to 91% (20/22).<sup>46</sup>

#### Endoscopic internal drainage

In some patients treated by stents, a leak cavity persists after removal of the stent, this persistence of leakage can be seen endo-

scopically and confirmed by contrast injection. It has been noted; however, that some of these patients do not suffer clinically from these persistent cavities, this has been noted also by surgeons in some patients undergoing conservative management.<sup>22,27</sup> It seems that granulation tissue eventually forms a sealed cavity communicating with the lumen but not with the abdominal cavity. Based on this observation Donatelli et al<sup>47</sup> have devised an approach based on promoting the formation of such cavities. The technique involves inserting 1 or 2 double pigtail stents through the leak and exchanging them regularly over several weeks. These stents allow a constant internal drainage of any leaked fluid and eventually a sealed granulation tissue cavity is formed. Nasojejunal tubes are usually inserted to allow enteral feeding until healing occurs.

In their ongoing series of 67 patients, Donatelli et al<sup>48</sup> reported a success rate of 74% (50/67) so far. At the time of publication 9 patients were still undergoing treatment, there were 5 documented failures and 2 mortalities, this suggests that the eventual success rate will fall anywhere between 74% and 92%. The average number of endoscopies was 3.14 and the time to healing was 57 days. The technique seems to have several advantages including low cost and absence of stent-induced complications. The disadvantages include the need for repeated stent exchanges, use of nasojejunal feeding for several weeks and possibly a high incidence of stricture formation as 6 patients (9%) in this series developed stenosis. This may be one advantage supporting the use of SEMS as they simultaneously dilate any stenosis while allowing the leak to heal.



Fig. 5. The Overstitch device (Apollo Endosurgery).

### Suturing devices

Since the advent of endoscopy, a device that can perform surgical sutures endoscopically has been regarded as the holy grail of endoscopists. The Overstitch device (Apollo Endosurgery, Austin, TX, USA) is currently the closest device to achieve this target (Fig. 5). It is a disposable device able to place both absorbable (2-0 and 3-0 polydioxanone) and non-absorbable (2-0 and 3-0 polypropylene) sutures. The system allows continuous or interrupted stitches to be made of various lengths.<sup>49</sup> An *in vivo* study on human colons has showed safe subserosal positioning of all the sutures with no risk of injury to surrounding organs.<sup>50</sup>

Two initial case reports concluded success of the Overstitch in healing a chronic esophagopleural and a gastrocutaneous fistula.<sup>49,51</sup> Cai et al<sup>52</sup> reported successful closure of 2 sleeve gastrectomy leaks using the Overstitch; however, one had a stent inserted simultaneously. Recently, Sharaiha et al<sup>53</sup> reported results of a large multicentre series, indications for Overstitch were as follows: stent anchorage ( $n = 47$ ), fistulas ( $n = 40$ ), leaks ( $n = 15$ ), and perforations ( $n = 20$ ). Technical success was achieved in 97.5%. Clinical success was 91.4% in stent anchorage, 93% in perforations, 80% in fistulas, but only 27% in anastomotic leak closure.<sup>53</sup> The results highlight the different nature of iatrogenic endoscopic perforations and postsurgical leaks, moreover, they show how poorly sutures in particular perform in postsurgical leaks.

For postsurgical leaks, we as endoscopists should reach the conclusion reached by surgeons decades ago that simply putting a good suture on a surgical leak is not the solution. With infected, friable, devascularized leak edges it might be better to opt for stenting or the use of the elastic OTSC's with their constant compression or use endoscopic internal drainage, rather than putting a perfectly placed standard surgeon's suture. Suturing devices also remain to date costly and very technically demanding limiting their widespread use.

### Vacuum therapy

Vacuum assisted closure (VAC) is a well-established technique to promote healing of superficial wounds.<sup>54</sup> A vacuum-sealed sponge is inserted in the wound cavity and connected to a suction

device. This allows the constant removal of infected fluids, promotes rapid resolution of tissue edema and improves the micro-circulation in that area, leading to the rapid formation of granulation tissue.<sup>54</sup> The sponge has to be replaced every few days until wound healing occurs. The endoscopic version of this technique (EVAC) was probably first well-described by Nagell and Holte,<sup>55</sup> who described their experience with 4 patients with rectal anastomotic leaks. A sponge was inserted into the leak cavities and was connected to a suction device through the anus. Leaks healed by forming a granulation tissue lined cavity in all 4 patients at a mean of 51 days.<sup>55</sup> Larger series followed such as the one by Weidenhagen et al<sup>56</sup> where 29 patients with leaks after anterior rectal resection were treated by EVAC. Success was achieved in 28 patients (96%) with a mean of 11.4 endoscopies per patient. It should be noted, however, that 21 patients (72%) had a protective stoma.<sup>56</sup> The procedure seems to be well tolerated by patients, in the study by Riss et al<sup>57</sup> 9 patients treated by EVAC for rectal anastomotic leaks had a median visual analogue pain score of 3 (0–6) on a scale of up to 10. Six out of the 9 patients said they were willing to be retreated with EVAC.

The technique has been recently used for post-esophagectomy leaks. Wedemeyer et al<sup>58</sup> treated 8 patients with post-esophagectomy leaks using EVAC. Leaks healed in 7 patients (88%) in a mean of 23 days and 7 endoscopies per patient. Recent studies have compared EVAC to stent therapy for the management of leaks.<sup>20,59</sup> In one study, 39 patients were treated by SEMS or SEPS while 32 were treated by EVAC. Leak healing occurred in 84% of EVAC group vs 54% in the stent group with no difference in hospitalization or mortality. Strictures were also seen more commonly with stents (28% vs 9%;  $P < 0.05$ ).<sup>20</sup> The results are intriguing but selection bias for the method of treatment has to be considered as these patients were not randomized, the initial surgical procedures in both groups were also significantly different.

The results of EVAC are certainly impressive but the enthusiasm has to be taken with caution. Complications have been reported such as fistula formation with small intestinal loops and the aorta.<sup>60</sup> The major drawback seems to be the need for numerous endoscopic procedures and probably the need for prolonged hospitalization. The technique also by default needs a cavity large enough to accommodate the sponge and prolonged TPN is usually necessary for those with esophageal leaks. Nevertheless, the technique is a very welcome addition to the armamentarium of techniques for leak closure, and may be especially useful in large refractory leaks.

### Tissue sealants

The use of tissue sealants and adhesives is a well-established surgical concept.<sup>61</sup> Fibrin glue (Tissucol Duo, Baxter, Germany) is composed of fibrinogen and thrombin which when injected simultaneously into the fistulous tract form a three-dimensional gel within 10 to 60 seconds, an "acellular clot". This gel acts as a scaffold for regenerating tissues thus promoting healing.<sup>62</sup> Some authors have advocated the injection of fibrin submucosally at the leak edges rather than inside the fistula.<sup>63</sup> N-butyl-2-cyanoacrylate (Histoacryl; B. Braun, Tuttlingen, Germany) on the other hand is a pure adhesive, after contact with liquids it almost instantly solidifies and occludes the fistulous cavity.<sup>64</sup> Cyanoacrylate is also irritant to the surrounding tissues promoting an inflammatory reaction which is thought to improve vascularity and healing.

Eleftheriadis et al<sup>65</sup> published one of the earliest reports on endoscopic application of fibrin glue to treat post-operative enterocutaneous fistulas. All seven patients included were treated



successfully. Several case reports and a few small case series then followed with success rates ranging between 50% to 86%.<sup>64,66,67</sup> Recently, some authors combined fibrin glue with a Vicryl mesh (Ethicon, Hamburg, Germany).<sup>68</sup> The mesh is inserted inside the leak cavity and then fibrin glue is injected onto the mesh and submucosally at the leak edges. Using this method Böhm et al<sup>69</sup> reported success in 13 out of 15 patients in 1 to 4 sessions.

In general, sealants and adhesives may be useful in small leaks with long tracts that can accommodate a significant amount of the sealant. Larger leaks and acute perforations with no tracts will usually not be suitable. For post-surgical leaks the main role of sealants and glue is currently that of an adjunctive therapy to clips or stents.

## Conclusion

Postsurgical GI leaks are serious complications with significant morbidity and mortality. Several endoscopic techniques have shown efficacy and a favourable safety profile. Nevertheless, to date, most evidence comes from retrospective case series. Choice of technique depends on several factors including site, size and duration of leak, operator familiarity with the techniques and availability. Different endoscopic techniques should be considered complementary or interchangeable rather than competing. The combination of techniques is frequently effective, endoscopists should not be afraid to be innovative and to combine the techniques when appropriate, assuming the operator has sufficient experience in managing such cases.

## Conflicts of Interest

No potential conflict of interest relevant to this article was reported.

## References

- Rutegård M, Lagergren P, Rouvelas I, Lagergren J. Intrathoracic anastomotic leakage and mortality after esophageal cancer resection: a population-based study. *Ann Surg Oncol*. 2012;19:99-103.
- Higa KD, Boone KB, Ho T. Complications of the laparoscopic Roux-en-Y gastric bypass: 1,040 patients—what have we learned? *Obes Surg*. 2000;10:509-13.
- Lang H, Piso P, Stukenborg C, Raab R, Jähne J. Management and results of proximal anastomotic leaks in a series of 1114 total gastrectomies for gastric carcinoma. *Eur J Surg Oncol*. 2000;26:168-71.
- Marshall JS, Srivastava A, Gupta SK, Rossi TR, DeBord JR. Roux-en-Y gastric bypass leak complications. *Arch Surg*. 2003;138:520-3.
- Sakran N, Goitein D, Raziel A, Keidar A, Beglaibter N, Grinbaum R, et al. Gastric leaks after sleeve gastrectomy: a multicenter experience with 2,834 patients. *Surg Endosc*. 2013;27:240-5.
- Fernandez AZ Jr, DeMaria EJ, Tichansky DS, Kellum JM, Wolfe LG, Meador J, et al. Experience with over 3,000 open and laparoscopic bariatric procedures: multivariate analysis of factors related to leak and resultant mortality. *Surg Endosc*. 2004;18:193-7.
- Alanezi K, Urschel JD. Mortality secondary to esophageal anastomotic leak. *Ann Thorac Cardiovasc Surg*. 2004;10:71-5.
- Francone TD, Saleem A, Read TA, Roberts PL, Marcello PW, Schoetz DJ, et al. Ultimate fate of the leaking intestinal anastomosis: does leak mean permanent stoma? *J Gastrointest Surg*. 2010;14:987-92.
- Rullier E, Laurent C, Garrelon JL, Michel P, Saric J, Parneix M. Risk factors for anastomotic leakage after resection of rectal cancer. *Br J Surg*. 1998;85:355-8.
- Lindgren R, Hallböök O, Rutegård J, Sjödahl R, Matthiessen P. What is the risk for a permanent stoma after low anterior resection of the rectum for cancer? A six-year follow-up of a multicenter trial. *Dis Colon Rectum*. 2011;54:41-7.
- Dudrick SJ, Maharaj AR, McKelvey AA. Artificial nutritional support in patients with gastrointestinal fistulas. *World J Surg*. 1999;23:570-6.
- Chung MA, Wanebo HJ. Surgical management and treatment of gastric and duodenal fistulas. *Surg Clin North Am*. 1996;76:1137-46.
- Karl RC, Schreiber R, Boulware D, Baker S, Coppola D. Factors affecting morbidity, mortality, and survival in patients undergoing Ivor Lewis esophagogastricomy. *Ann Surg*. 2000;231:635-43.
- van Bodegraven AA, Kuipers EJ, Bonenkamp HJ, Meuwissen SG. Esophagopleural fistula treated endoscopically with argon beam electrocoagulation and clips. *Gastrointest Endosc*. 1999;50:407-9.
- Shehab HM, Elasmr HM. Combined endoscopic techniques for closure of a chronic post-surgical gastrocutaneous fistula: case report and review of the literature (with video). *Surg Endosc*. 2013;27:2967-70.
- Evrard S, Le Moine O, Lazaraki G, Dormann A, El Nakadi I, Devière J. Self-expanding plastic stents for benign esophageal lesions. *Gastrointest Endosc*. 2004;60:894-900.
- Holm AN, de la Mora Levy JG, Gostout CJ, Topazian MD, Baron TH. Self-expanding plastic stents in treatment of benign esophageal conditions. *Gastrointest Endosc*. 2008;67:20-5.
- Dai Y, Chopra SS, Kneif S, Hünnerbein M. Management of esophageal anastomotic leaks, perforations, and fistulae with self-expanding plastic stents. *J Thorac Cardiovasc Surg*. 2011;141:1213-7.
- van Halsema EE, van Hooft JE. Clinical outcomes of self-expandable stent placement for benign esophageal diseases: a pooled analysis of the literature. *World J Gastrointest Endosc*. 2015;7:135-53.
- Brangewitz M, Voigtländer T, Helfritz FA, Lankisch TO, Winkler M, Klempnauer J, et al. Endoscopic closure of esophageal intrathoracic leaks: stent versus endoscopic vacuum-assisted closure, a retrospective analysis. *Endoscopy*. 2013;45:433-8.
- van Boeckel PG, Dua KS, Weusten BL, Schmits RJ, Surapaneni N, Timmer R, et al. Fully covered self-expandable metal stents (SEMS), partially covered SEMS and self-expandable plastic stents for the treatment of benign esophageal ruptures and anastomotic leaks. *BMC Gastroenterol*. 2012;12:19.
- David EA, Kim MP, Blackmon SH. Esophageal salvage with removable covered self-expanding metal stents in the setting of intrathoracic esophageal leakage. *Am J Surg*. 2011;202:796-801.
- Feith M, Gillen S, Schuster T, Theisen J, Friess H, Gertler R. Healing occurs in most patients that receive endoscopic stents for anastomotic leakage; dislocation remains a problem. *Clin Gastroenterol Hepatol*. 2011;9:202-10.
- El Hajj II, Imperiale TF, Rex DK, Ballard D, Kesler KA, Birdas TJ, et al. Treatment of esophageal leaks, fistulae, and perforations with temporary stents: evaluation of efficacy, adverse events, and factors associated with successful outcomes. *Gastrointest Endosc*. 2014;79:589-98.
- Gubler C, Bauerfeind P. Self-expandable stents for benign esophageal leakages and perforations: long-term single-center experience. *Scand J Gastroenterol*. 2014;49:23-9.
- Orive-Calzada A, Calderón-García Á, Bernal-Martínez A, Díaz-Roca AB, Barrio-Beraza I, Cabriada-Nuño JL, et al. Closure of benign leaks, perforations, and fistulas with temporary placement of fully covered metal stents: a retrospective analysis. *Surg Laparosc Endosc Percutan Tech*. 2014;24:528-36.
- Leenders BJ, Stronkhorst A, Smulders FJ, Nieuwenhuijzen GA, Gilissen LP. Removable and repositionable covered metal self-expandable stents for leaks after upper gastrointestinal surgery: experiences in a tertiary referral hospital. *Surg Endosc*. 2013;27:2751-9.
- Bège T, Emungania O, Vitton V, Ah-Soune P, Nocca D, Noël P, et al. An endoscopic strategy for management of anastomotic complications from bariatric surgery: a prospective study. *Gastrointest Endosc*. 2011;73:238-44.
- Puli SR, Spofford IS, Thompson CC. Use of self-expandable stents in the treatment of bariatric surgery leaks: a systematic review and meta-analysis. *Gastrointest Endosc*. 2012;75:287-93.
- van Heel NC, Haringsma J, Spaander MC, Bruno MJ, Kuipers EJ. Short-term esophageal stenting in the management of benign perforations. *Am J Gastroenterol*. 2010;105:1515-20.
- van Boeckel PG, Sijbrink A, Vleggaar FP, Siersema PD. Systematic review: temporary stent placement for benign rupture or anastomotic leak of the oesophagus. *Aliment Pharmacol Ther*. 2011;33:1292-301.
- Puig CA, Waked TM, Baron TH Sr, Wong Kee Song LM, Gutierrez J, Sarr MG. The role of endoscopic stents in the management of chronic anastomotic and staple line leaks and chronic strictures after bariatric surgery. *Surg Obes Relat Dis*. 2014;10:613-7.
- Donatelli G, Dhumane P, Perretta S, Dallemagne B, Vix M, Mutter D, et al. Endoscopic placement of fully covered self expanding metal stents for management of post-operative foregut leaks. *J Minim Access Surg*. 2012;8:118-24.
- Swinnen J, Eisendrath P, Rigaux J, Kahegeshe L, Lemmers A, Le Moine O, et al. Self-expandable metal stents for the treatment of benign upper GI leaks and perforations. *Gastrointest Endosc*. 2011;73:890-9.
- Babor R, Talbot M, Tyndal A. Treatment of upper gastrointestinal leaks with a removable, covered, self-expanding metallic stent. *Surg Laparosc Endosc Percutan Tech*. 2009;19:e1-4.
- Fukumoto R, Orlina J, McGinty J, Teixeira J. Use of polyflex stents in treatment of acute esophageal and gastric leaks after bariatric surgery. *Surg Obes Relat Dis*. 2007;3:68-71.
- Merrifield BF, Lautz D, Thompson CC. Endoscopic repair of gastric leaks after Roux-en-Y gastric bypass: a less invasive approach. *Gastrointest Endosc*. 2006;63:710-4.
- Binmoeller KF, Grimm H, Soehendra N. Endoscopic closure of a perforation using metallic clips after snare excision of a gastric leiomyoma. *Gastrointest Endosc*. 1993;39:172-4.
- Yoshikane H, Hidano H, Sakakibara A, Ayakawa T, Mori S, Kawashima H, et al. Endoscopic repair by clipping of iatrogenic colonic perforation. *Gastrointest Endosc*. 1997;46:464-6.
- Hagel AF, Naegel A, Lindner AS, Kessler H, Matzel K, Dauth W, et al. Over-the-scope clip application yields a high rate of closure in gastrointestinal perforations and may reduce emergency surgery. *J Gastrointest Surg*. 2012;16:2132-8.



41. Parodi A, Repici A, Pedroni A, Bianchi S, Conio M. Endoscopic management of GI perforations with a new over-the-scope clip device (with videos). *Gastrointest Endosc.* 2010;72:881–6.
42. Sandmann M, Heike M, Faehndrich M. Application of the OTSC system for the closure of fistulas, anastomosal leakages and perforations within the gastrointestinal tract. *Z Gastroenterol.* 2011;49:981–5.
43. Haito-Chavez Y, Law JK, Kratt T, Arezzo A, Verra M, Morino M, et al. International multicenter experience with an over-the-scope clipping device for endoscopic management of GI defects (with video). *Gastrointest Endosc.* 2014;80:610–22.
44. Mercky P, Gonzalez JM, Aimore Bonin E, Emungania O, Brunet J, Grimaud JC, et al. Usefulness of over-the-scope clipping system for closing digestive fistulas. *Dig Endosc.* 2015;27:18–24.
45. Famik H, Driller M, Kratt T, Schmidt C, Fährndrich M, Filmann N, et al. Indication for 'Over the scope' (OTS)-clip vs. covered self-expanding metal stent (cSEMS) is unequal in upper gastrointestinal leakage: results from a retrospective head-to-head comparison. *PLoS One.* 2015;10:e0117483.
46. Shehab HM, Hakky SM, Gawdat KA. An endoscopic strategy combining Mega stents and over-the-scope clips for the management of post-bariatric surgery leaks and fistulas (with video). *Obes Surg.* 2015. doi: 10.1007/s11695-015-1950-x. [Epub ahead of print]
47. Donatelli G, Ferretti S, Vergeau BM, Dhumeau P, Dumont JL, Derhy S, et al. Endoscopic Internal Drainage with Enteral Nutrition (EDEN) for treatment of leaks following sleeve gastrectomy. *Obes Surg.* 2014;24:1400–7.
48. Donatelli G, Dumont JL, Cereatti F, Ferretti S, Vergeau BM, Tuszyński T, et al. Treatment of leaks following sleeve gastrectomy by endoscopic internal drainage (EID). *Obes Surg.* 2015;25:1293–301.
49. Bonin EA, Wong Kee Song LM, Gostout ZS, Bingener J, Gostout CJ. Closure of a persistent esophagopleural fistula assisted by a novel endoscopic suturing system. *Endoscopy.* 2012;44(Suppl 2):E8–9.
50. Pauli EM, Delaney CP, Champagne B, Stein S, Marks JM. Safety and effectiveness of an endoscopic suturing device in a human colonic treat-and-resect model. *Surg Innov.* 2013;20:594–9.
51. Kantsevov SV, Thuluvath PJ. Successful closure of a chronic refractory gastrocutaneous fistula with a new endoscopic suturing device (with video). *Gastrointest Endosc.* 2012;75:688–90.
52. Cai JX, Khashab MA, Okolo PI 3rd, Kalloo AN, Kumbhari V. Full-thickness endoscopic suturing of staple-line leaks following laparoscopic sleeve gastrectomy. *Endoscopy.* 2014;46(Suppl 1):E623–4.
53. Shariha RZ, Kumta NA, DeFilippis EM, Dimaio CJ, Gonzalez S, Gonda T, et al. A large multicenter experience with endoscopic suturing for management of gastrointestinal defects and stent anchorage in 122 patients: a retrospective review. *J Clin Gastroenterol.* 2015. doi: 10.1097/MCG.0000000000000336. [Epub ahead of print]
54. Krokowicz L, Borejsza-Wysocki M, Mackiewicz J, Iqbal A, Drews Michal. 10 years of negative pressure wound therapy [NPWT]: evolution of indications for its use. *Negat Press Wound Ther.* 2014;1:27–32.
55. Nagell CF, Holte K. Treatment of anastomotic leakage after rectal resection with transrectal vacuum-assisted drainage (VAC): a method for rapid control of pelvic sepsis and healing. *Int J Colorectal Dis.* 2006;21:657–60.
56. Weidenhagen R, Gruetzner KU, Wiecken T, Spelsberg F, Jauch KW. Endoscopic vacuum-assisted closure of anastomotic leakage following anterior resection of the rectum: a new method. *Surg Endosc.* 2008;22:1818–25.
57. Riss S, Stift A, Meier M, Haiden E, Grünberger T, Bergmann M. Endo-sponge assisted treatment of anastomotic leakage following colorectal surgery. *Colorectal Dis.* 2010;12(7 Online):e104–8.
58. Wedemeyer J, Brangewitz M, Kubicka S, Jackobs S, Winkler M, Neipp M, et al. Management of major postsurgical gastroesophageal intrathoracic leaks with an endoscopic vacuum-assisted closure system. *Gastrointest Endosc.* 2010;71:382–6.
59. Mennigen R, Harting C, Lindner K, Vowinkel T, Rijcken E, Palmes D, et al. Comparison of endoscopic vacuum therapy versus stent for anastomotic leak after esophagectomy. *J Gastrointest Surg.* 2015;19:1229–35.
60. Ahrens M, Schulte T, Egberts J, Schafmayer C, Hampe J, Fritscher-Ravens A, et al. Drainage of esophageal leakage using endoscopic vacuum therapy: a prospective pilot study. *Endoscopy.* 2010;42:693–8.
61. Reece TB, Maxey TS, Kron IL. A prospectus on tissue adhesives. *Am J Surg.* 2001;182(2 Suppl):40S–4S.
62. Spotnitz WD. Fibrin sealant: past, present, and future: a brief review. *World J Surg.* 2010;34:632–4.
63. Farra J, Zhuge Y, Neville HL, Thompson WR, Sola JE. Submucosal fibrin glue injection for closure of recurrent tracheoesophageal fistula. *Pediatr Surg Int.* 2010;26:237–40.
64. Pramateftakis MG, Vrakas G, Kanellos I, Mantzoros I, Angelopoulos S, Eleftheriades E, et al. Endoscopic application of n-butyl-2-cyanoacrylate on esophagojejunal anastomotic leak: a case report. *J Med Case Rep.* 2011;5:96.
65. Eleftheriadis E, Tzartinoglou E, Kotzampassi K, Aletras H. Early endoscopic fibrin sealing of high-output postoperative enterocutaneous fistulas. *Acta Chir Scand.* 1990;156:625–8.
66. Rábago LR, Ventosa N, Castro JL, Marco J, Herrera N, Gea F. Endoscopic treatment of postoperative fistulas resistant to conservative management using biological fibrin glue. *Endoscopy.* 2002;34:632–8.
67. Cellier C, Landi B, Faye A, Wind P, Frileux P, Cugnenc PH, et al. Upper gastrointestinal tract fistulae: endoscopic obliteration with fibrin sealant. *Gastrointest Endosc.* 1996;44:731–3.
68. Truong S, Böhm G, Klinge U, Stumpf M, Schumpelick V. Results after endoscopic treatment of postoperative upper gastrointestinal fistulas and leaks using combined Vicryl plug and fibrin glue. *Surg Endosc.* 2004;18:1105–8.
69. Böhm G, Mossdorf A, Klink C, Klinge U, Jansen M, Schumpelick V, et al. Treatment algorithm for postoperative upper gastrointestinal fistulas and leaks using combined vicryl plug and fibrin glue. *Endoscopy.* 2010;42:599–602.