

# Gastrointestinal Intervention

journal homepage: [www.gi-intervention.org](http://www.gi-intervention.org)

## Review Article

## Which is better for unresectable malignant hilar biliary obstruction: Side-by-side versus stent-in-stent?



Itaru Naitoh,<sup>1,\*</sup> Tadahisa Inoue,<sup>2</sup> Kazuki Hayashi<sup>1</sup>

### ABSTRACT

Biliary drainage is required for the management of unresectable malignant hilar biliary obstruction (UMHBO), and endoscopic transpapillary drainage is the first-line therapy because it is less invasive. Self-expandable metallic stents (SEMSs) are superior to plastic stents because they have longer stent patency and are more cost-effective. Endoscopic bilateral SEMS placement is technically challenging compared to unilateral placement. However, recent developments in devices and techniques have facilitated bilateral SEMS placement. There are two methods for bilateral hilar SEMS placement for UMHBO: side-by-side (SBS) and stent-in-stent (SIS). Sequential SBS was commonly conducted for bilateral hilar SEMS placement. In a new and thinner delivery system that was developed for SEM placement, two SEMSs could be simultaneously inserted and deployed through the working channel. This new bilateral stenting method enabled us to accomplish simultaneous SBS placement, which increased the success rate of SBS. Insertion of the guidewire and delivery of the second SEMS through the mesh of the first SEMS is challenging in SIS. Newly designed or modified SEMSs that are suitable for SIS have been developed to overcome this challenge, and these SEMSs have facilitated SIS. Uncovered SEMS has been commonly used for hilar SEMS placement, but covered SEMS (CSEMS) is another option for hilar SEMS placement, because CSEMS prevents tumor ingrowth and allows for removal of the stent for re-intervention. Therefore, CSEMS can be used for bilateral SEMS placement in SBS. There are many methods and kinds of SEMS available for bilateral SEMS placement. However, due to lack of evidence, there is no consensus on whether SBS or SIS is optimal for bilateral hilar SEMS placement. In this review, we compared various outcomes between SBS and SIS from previous studies, to clarify which method is better for bilateral SEMS placement for UMHBO.

Copyright © 2018, Society of Gastrointestinal Intervention.

**Keywords:** Cholangiopancreatography, endoscopic retrograde; Cholestasis; Klatskin tumor; Self expandable metallic stents

## Introduction

Endoscopic biliary drainage with self-expandable metallic stents (SEMS) is superior to plastic stents for unresectable malignant hilar biliary obstruction (UMHBO), with a life expectancy of > 3 months, because it is less invasive, has long-term stent patency and is more cost-effective.<sup>1–4</sup> No consensus has been reached on whether unilateral or bilateral drainage is optimal for UMHBO.<sup>4–10</sup> Liver volume and function are important factors for determining the drainage area in UMHBO. Drainage of more than 50% of the liver volume, which frequently requires bilateral stent placement, seems to be an important predictor of drainage effectiveness in UMHBO.<sup>11,12</sup> Bilateral drainage is also required for the treatment of segmental cholangitis or jaundice after unilateral

biliary drainage. Unilateral drainage shows a significantly higher technical success rate and lower adverse event rate than bilateral drainage, which is technically difficult and requires multiple complex procedures. A recent randomized controlled trial comparing unilateral and bilateral SEMS placement revealed that endoscopic bilateral SEMS placement was more effective than unilateral SEMS placement in terms of stent patency and survival in advanced UMHBO.<sup>13</sup>

There are two methods for bilateral hilar SEMS placement for UMHBO: side-by-side (SBS) and stent-in-stent (SIS).<sup>13</sup> Endoscopic bilateral SEMS placement is challenging, and sequential SBS has been performed previously.<sup>7,12,14</sup> However, recent developments in devices and techniques for endoscopic intervention allowed for endoscopic bilateral SEMS placement to be performed more

<sup>1</sup>Department of Gastroenterology and Metabolism, Nagoya City University Graduate School of Medical Sciences, Nagoya, Japan

<sup>2</sup>Department of Gastroenterology, Aichi Medical University School of Medicine, Nagakute, Japan

Received April 26, 2018; Revised June 22, 2018; Accepted June 22, 2018

\* Corresponding author. Department of Gastroenterology and Metabolism, Nagoya City University Graduate School of Medical Sciences, 1 Kawasumi, Mizuho-cho, Mizuho-ku, Nagoya 467-8601, Japan.

E-mail address: [inaito@med.nagoya-cu.ac.jp](mailto:inaito@med.nagoya-cu.ac.jp) (I. Naitoh). ORCID: <https://orcid.org/0000-0001-8342-886X>

commonly. SIS using laser-cut type stents and open-cell type stents showed higher technical success rates than previous types of SEMS.<sup>15–17</sup> Simultaneous SBS using a thin delivery system was also recently reported. Furthermore, SBS using covered SEMS (CSEMS) is another option for bilateral hilar SEMS placement. However, the optimal method for bilateral SEMS placement has been under debate. There is currently no consensus regarding whether SBS or SIS should be used in bilateral SEMS placement for UMHB0. Here, we review the current literature concerning SBS and SIS in endoscopic bilateral SEMS placement for UMHB0.

## Side-by-Side Method

### Sequential side-by-side method

The conventional sequential SBS technique involves the following steps. (a) Two guidewires are inserted into the targeted intrahepatic bile ducts. (b) The first SEMS is inserted into the targeted intrahepatic bile duct along the guidewire and deployed. (c) The second SEMS is inserted into a contralateral bile duct along the other guidewire and deployed. (d) The two SEMSs are parallel to each other in the common bile duct. The distal sides of the two SEMSs should be deployed at the same level as the common bile duct to facilitate endoscopic re-intervention for recurrent biliary obstruction (RBO) when the two SEMS are placed above the papilla (Fig. 1). The distal sides of the two SEMSs are more commonly located above rather than across the papilla. SBS above the papilla may be associated with longer time to RBO by reducing duodenobiliary reflux, and it decreases the risk of post-procedure pancreatitis compared to SBS across the papilla. On the contrary, re-intervention is technically easier in SBS across the papilla, and we can easily remove the occluded SEMS for re-intervention when we use fully covered SEMS (FCSEMS) across the papilla. However, there have been no comparative studies between SBS above the papilla and across the papilla. The most difficult step of the sequential SBS method is insertion of the second SEMS along the first SEMS. After deployment of the first SEMS in the common bile duct, delivery of the second SEMS could not pass beyond the distal edge of the first expanded SEMS in failure cases (Fig. 2). The technical success rates of sequential SBS vary from

73% to 97% (Table 1).<sup>14,15,17–23</sup>

Uncovered SEMSs (USEMSs) with diameters of 8 mm or 10 mm are commonly used for UMHB0. Lee et al<sup>14</sup> compared 8- and 10-mm diameter USEMSs in SBS and found that the functional success rate and successful endoscopic re-intervention rate did not differ; however, the 10-mm diameter SEMS tended to have a greater stent patency (median, 180 days vs 149 days;  $P = 0.117$ ). There is no consensus on whether the 8- or 10-mm diameter SEMS should be used in SBS. We usually select the SEMS diameter based on the diameter of the common bile duct.

### Simultaneous side-by-side method

Recently, a thinner delivery system (6-Fr) was developed that enabled two SEMSs to be simultaneously inserted and deployed through the accessory channel of a therapeutic duodenoscope after SEMS.<sup>15–17</sup> This new bilateral stenting method enabled us to

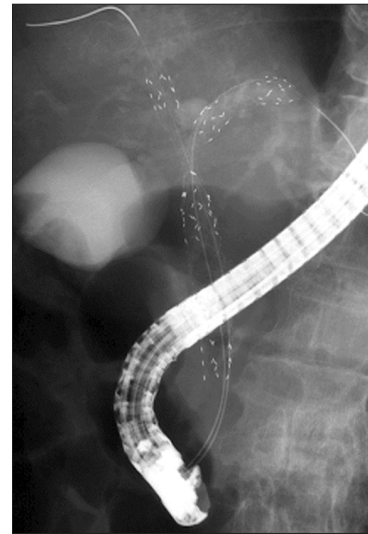

Fig. 1. Side-by-side method.

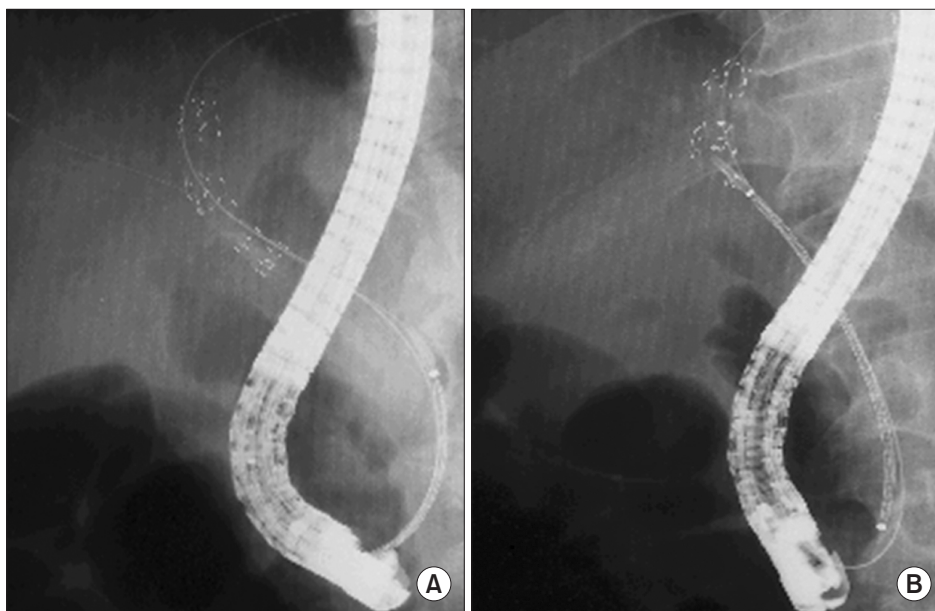


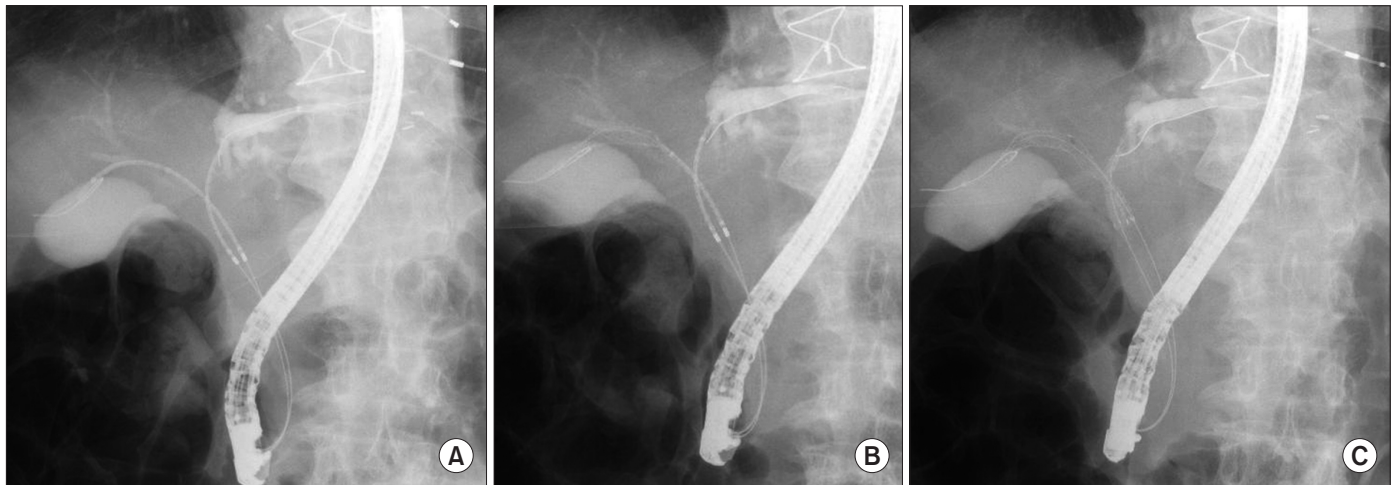
Fig. 2. Technical failure in sequential side-by-side method. (A) First self-expanding metal stent (SEMS) is deployed in the left bile duct. (B) Second SEMS could not pass beyond the distal edge of the first expanded SEMS.

Table 1 Previous Studies of Side-by-Side Methods

Author (year)	No. of patients	Method	Type of SEMS	Technical success	Functional success	The incidence of RBO	Time to RBO (mo)	Adverse event other than RBO	Cholecystitis
Dumas et al <sup>18</sup> (2000)	45	Sequential	USEMS	73.3 (33/45)	100 (33/33)	3.0 (1/33)	N/A	3.0 (1/33)	0
Cheng et al <sup>19</sup> (2002)	36	Sequential	USEMS	97.2 (35/36)	N/A	31.4 (11/35)	5.6	8.6 (3/35)	0
Chennat et al <sup>15</sup> (2010)	10	Simultaneous	USEMS	100 (10/10)	N/A	N/A	N/A	N/A	0
Naitoh et al <sup>20</sup> (2012)	28	Sequential	USEMS	89.3 (25/28)	96.0 (24/25)	20.0 (5/25)	15.6	44.0 (11/25)	16.0 (4/25)
Lee et al <sup>14</sup> (2013)	44	Sequential	USEMS	90.9 (40/44)	97.5 (39/40)	45.0 (18/40)	5.2	9.1 (4/44)	2.3 (1/44)
Kawakubo et al <sup>17</sup> (2015)	13	Simultaneous	USEMS	84.6 (11/13)	N/A	38.5 (5/13)	8.8	38.5 (5/13)	7.7 (1/13)
Yoshida et al <sup>21</sup> (2016)	32	Sequential	CSEMS	96.9 (31/32)	93.5 (29/31)	61.3 (19/31)	3.2	9.4 (3/32)	3.1 (1/32)
Inoue et al <sup>22</sup> (2017)	17	Simultaneous	USEMS	100 (17/17)	100 (17/17)	47.1 (8/17)	4.7	11.8 (2/17)	0
Kitamura et al <sup>23</sup> (2017)	17	Sequential	CSEMS	100 (17/17)	82.4 (14/17)	70.6 (12/17)	2.6	5.9 (1/17)	0

Values are presented as number only, % (number/total number), or median only.

SEMS, self-expandable metal stent; USEMS, uncovered SEMS; CSEMS, covered SEMS; N/A, not applicable; RBO, recurrent biliary obstruction.



**Fig. 3.** Simultaneous side-by-side (SBS) method. (A) Two self-expandable metal stent (SEMS) delivery systems are simultaneously inserted through the working channel. (B) Two SEMSs are simultaneously deployed. (C) Two SEMSs are placed in a SBS configuration.

accomplish simultaneous SBS placement. The simultaneous SBS technique involves the following steps (Fig. 3). (a) Two guidewires are inserted into the targeted intrahepatic bile ducts. (b) Two SEMSs are then simultaneously inserted into the targeted intrahepatic bile ducts along each guidewire through the working channel. (c) The two SEMSs are then simultaneously or sequentially deployed. (d) The two SEMSs are parallel to each other in the common bile duct. Theoretically, simultaneous SBS can avoid failure of insertion of the second SEMS in sequential SBS after the two guidewires are inserted into the targeted intrahepatic bile ducts. The technical success rate of simultaneous SBS (85%–100%) is higher than that of sequential SBS (73%–91%) (Table 1).<sup>14,15,17–23</sup> Inoue et al<sup>22</sup> retrospectively compared sequential SBS and simultaneous SBS using a novel SEMS with a 5.7-Fr ultra-thin delivery system. The technical success rate was significantly higher in the simultaneous than sequential SBS group (100% vs 71%;  $P = 0.045$ ). The median procedure time was significantly shorter in the simultaneous than sequential SBS group (22 minutes vs 52 minutes;  $P = 0.017$ ). Therefore, the simultaneous SBS method might be a good option for bilateral hilar SEMS placement because it has a higher success rate and shorter procedure time than sequential SBS.

### Side-by-side method with CSEMS

USEMS is typically used for drainage of the UMHB, because the membrane in CSEMS might occlude the side branch of the intrahepatic bile duct. One disadvantage of USEMS is that it cannot prevent tumor ingrowth. Another disadvantage is that removal of USEMS is usually difficult during re-intervention after RBO. To reduce the occurrence of tumor ingrowth, ensure that the CSEMS can be easily removed during intervention after RBO, and reduce the risk of intrahepatic bile duct obstruction, a 6-mm diameter CSEMS was developed. Three retrospective studies examining the use of 6-mm diameter CSEMSs have been reported to date.<sup>21,23,24</sup> When 6-mm diameter CSEMSs were used, the time to RBO ranged from 2.6 to 7 months, which is shorter than the time associated with the use of 8- or 10-mm diameter USEMS. Tumor ingrowth was not observed with the use of 6-mm diameter CSEMS, and the causes of RBO were sludge formation and tumor overgrowth. Kanno et al<sup>25</sup> reported that soft surface irregularity of the perihilar malignancy in cholangiography was a significant risk factor for a shorter time to RBO in multiple SEMS placement. Most of the RBO cases were associated with tumor ingrowth in their study. Therefore, we consider the presence of this type of tumor to be

**Table 2** Previous Studies of Re-Intervention for RBO

Author (year)	No. of patients	Method	The incidence of RBO	Successful endoscopic re-intervention	Successful endoscopic bilateral re-intervention
Naitoh et al <sup>20</sup> (2012)	25	SBS	20.0 (5/25)	100 (5/5)	N/A
Lee et al <sup>14</sup> (2013)	40	SBS	45.0 (18/40)	92.3 (12/13)	50.0 (6/12)
Law and Baron <sup>16</sup> (2013)	17	SBS	52.9 (9/17)	75.0 (6/8)	75.0 (6/8)
Fujii et al <sup>26</sup> (2013)	55	SIS	54.5 (30/55)	100 (30/30)	66.7 (20/30)
Lee et al <sup>27</sup> (2013)	78	SIS	30.8 (24/78)	95.8 (23/24)	83.3 (20/24)
Naitoh et al <sup>28</sup> (2015)	72	SIS	50.0 (36/72)	97.1 (34/35)	51.4 (18/35)
Hong et al <sup>29</sup> (2017)	52	SIS	38.5 (20/52)	60.0 (12/20)	30.0 (6/20)

Values are presented as number only or % (number/total number).

RBO, recurrent biliary obstruction; SBS, side-by-side method; SIS, stent-in-stent method; N/A, not applicable.

an indication for CSEMS. The success rate of FCSEMS removal for re-intervention after RBO was 100%, respectively.<sup>21,24</sup> On the other hand, the success rate of partially covered SEMS (PCSEMS) removal was 60.0% (6 out of 10 patients) because tumor ingrowth involved the uncovered part of PCSEMS.<sup>23</sup> The success rate of SEMS removal for re-intervention after RBO may be higher when a 6-mm diameter CSEMS is used instead of USEMS. FCSEMS might be better than PCSEMS from the viewpoint of stent removal during re-intervention among CSEMS.

A concerning disadvantage of CSEMS is that intrahepatic bile duct occlusion can occur with the use of CSEMS for UMHB. Inoue et al<sup>24</sup> reported that liver abscesses occurred in 2 out of 17 cases (11.8%) when 6-mm FCSEMSs were used. The posterior bile ducts were occluded because these two cases were classified as Bismuth type III or IV, and FCSEMSs were placed across the posterior bifurcation. Yoshida et al<sup>21</sup> reported that liver abscesses occurred in 2 out of 32 cases (6.3%) when 6-mm FCSEMSs were used. However, the site of the abscess was apart from the inserted stent, and it is unclear if the abscess occurred due to obstruction of a side branch by the CSEMS, or due to other causes such as reflux of intestinal bacteria (which can occur with USEMS or plastic stents). The indications for FCSEMS should be considered carefully in patients who require placement across the intrahepatic bile duct bifurcation.

In two studies, 6-mm CSEMSs were placed across the duodenum papilla in 24 patients and 17 patients.<sup>21,23</sup> A concern in bilateral SEMS placement across the duodenum papilla is the occurrence of acute pancreatitis after SEMS placement. However, acute pancreatitis was not observed in these two studies. Therefore, we presume that the risk of acute pancreatitis is low in patients with 6-mm diameter bilateral CSEMS placement across the duodenum papilla.

### Outcomes of the side-by-side method

Previous studies that used the SBS method are summarized in Table 1.<sup>14,15,17-23</sup> The technical success rate of SBS was 73% to 100%, being higher in simultaneous SBS than sequential SBS. The functional success rate of SBS was 82% to 100%. The incidence rate of RBO was 3% to 47% and the time to RBO was 4.7 to 15.6 months in USEMS. On the other hand, the incidence rate of RBO was 61% to 71% and the time to RBO was 2.6 to 3.2 months in 6-mm CSEMS. The incidence rate of RBO was higher, and the time to RBO was shorter in 6-mm CSEMS than USEMS. The incidence rate of adverse events other than RBO was 3% to 44%. One study revealed a high incidence of cholecystitis (16%), which might have been associated with occlusion of the cystic

duct caused by excessive expansion of the biliary duct in the region of overlapping SEMSs<sup>20</sup>; however, the incidence of cholecystitis ranged from 0% to 3% in other previous studies. Previous studies that examined re-intervention for RBO are shown in Table 2.<sup>14,16,20,26-29</sup> The success rate of endoscopic re-intervention for SBS was 75% to 100%, and that of endoscopic bilateral re-intervention was 50% to 75%. The success rate of FCSEMS removal for re-intervention was 100% in two studies,<sup>21,24</sup> but that of PCSEMS was 60.0% (6/10) and 66.7% (4/6), respectively.<sup>21,23</sup> The success rate of SEMS removal for re-intervention was higher in 6-mm-diameter FCSEMS than PCSEMS, because tumor ingrowth involving the uncovered part of the partial CSEMS occurred with PCSEMS.

### Stent-in-Stent Method

The SIS technique involves the following steps. (a) Two guidewires are inserted into the targeted intrahepatic bile ducts. (b) The first SEMS is inserted into the targeted intrahepatic bile duct along the guidewire and deployed. (c) A new guidewire is inserted into the contralateral bile duct through the mesh of the first deployed SEMS. (d) The second SEMS is inserted into the contralateral bile duct along the new guidewire through the mesh of the first SEMS. (e) The second SEMS is deployed through the mesh of the first SEMS. (f) The two SEMSs are overlapped in the common bile duct (Fig. 4). Endoscopic sphincterotomy (EST) is commonly performed to reduce the risk of post-procedure pancreatitis because we generally need long procedure time for the diagnosis and treatment of malignant hilar biliary obstruction. Theoretically, EST is associated with reflux cholangitis because it causes a permanent reduction in biliary sphincter function. Therefore, EST might increase the incidence of RBO and time to RBO by sludge occlusion or non-occlusion cholangitis. However, there have been no previous studies comparing the outcome with and without EST before this procedure.

Insertion of the guidewire and delivery of the second SEMS through the mesh of the first SEMS are the most challenging steps in SIS. Newly designed SEMSs that are suitable for SIS were developed to overcome these challenges. Lee et al<sup>30</sup> reported a high technical success rate (8 out of 10 patients; 80.0%) with the use of these newly designed SEMS with a central wide-open mesh (Bonastent M-Hilar; Standard Sci Tech Inc., Seoul, Korea). In a prospective multicenter study using M-Hilar,<sup>31</sup> the success rate of a single session of SIS was 81.8% (27/33). The final technical and functional success rates were 94.3% (33/35) and 100% (33/33), respectively. Kogure et al<sup>32</sup> reported a high technical success rate (12 out of 12 patients; 100%) of SIS using a Niti-S large cell D-type



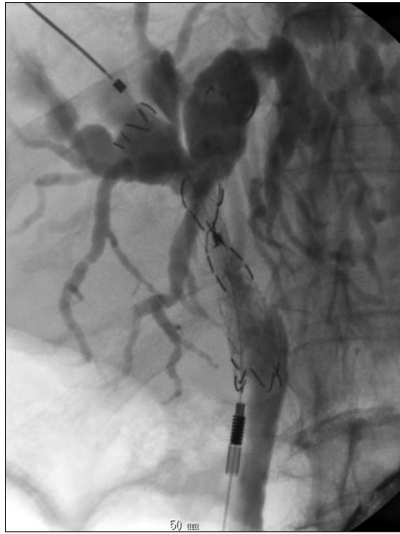

Fig. 4. Stent-in-stent method.

biliary stent (LCD; Taewoong Corp., Seoul, Korea). In a prospective multicenter study using the LCD,<sup>33</sup> the success rate of a single session of SIS was 96.2% (25/26). The final technical and functional success rates were 100% and 89%, respectively.

Braided type SEMS or laser-cut type SEMS are commonly used in SIS. Kawakubo et al<sup>34</sup> reported that the technical success rate was higher when a laser-cut type SEMS with a large mesh and thin delivery system was used, compared to use of a braided type SEMS with a small mesh and thick delivery system, in SIS for UMHB. Therefore, they concluded that the laser-cut type SEMS with a large mesh and thin delivery system might be preferable for the SIS procedure. Lee et al<sup>35</sup> compared the clinical outcomes of SIS between small cell-sized stents (SCS) (Bonastent M-Hilar; cell size 1.6 mm, delivery 7-Fr) and large cell-sized stents (LCS) (Niti-S large-cell D-type biliary stent; 6-mm cell size, delivery 8-Fr). There were no significant differences between the two groups in terms of the technical or functional success rate (SCS vs LCS, 100% vs 100%, respectively), or in the incidence of early adverse events (38.1% vs 18.2%), late adverse events (14.3% vs 22.7%) or stent occlusion (42.9% vs 45.5%). The time to RBO and overall survival were not significantly different between SCS and LCS ( $P = 0.086$  and  $P = 0.320$ , respectively). Sugimoto et al<sup>36</sup> compared the technical success and failure groups to clarify the factors predictive of SIS failure. They found that the type of the first SEMS (SCS or LCS) was not predictive of SIS failure ( $P = 0.26$ ), and the area of the first SEMS cell was not significantly different between the technical success and failure groups. Therefore, at the present time, it is difficult to conclude whether the SCS or LCS type of SEMS is superior for SIS.

Several studies have been conducted to identify the risk factors for technical failure of SIS for UMHB. Kawakubo et al<sup>34</sup> revealed that metastatic disease was a significant risk factor for technical failure of SIS (odds ratio, 9.63; 95% confidence interval, 1.11–105.5). Park et al<sup>37</sup> reported that the technical success rate was significantly higher in patients without masses obstructing the biliary confluence (MOCs) than patients with MOCs in SIS, using large cell type SEMS (95.2% vs 60.0%;  $P = 0.03$ ). Furthermore, the incidence of adverse events tended to be higher in patients with MOCs than without (50.0% vs 19.0%;  $P = 0.11$ ). They concluded that the risk of technical failure increased in patients with MOCs; therefore, caution is needed to prevent adverse events

in these patients. Sugimoto et al<sup>36</sup> revealed that the angle between the target biliary duct stricture and the first deployed SEMS was significantly larger in the failure group than the success group. There were significantly fewer guidewires or dilation devices (endoscopic retrograde cholangiopancreatography catheter, dilator, or balloon catheter) that passed the first SEMS cell in the failure group than in the success group. They concluded that a large angle was predictive of SIS failure.

Either an 8- or 10-mm diameter SEMS is commonly used for UMHB. Theoretically, a 10-mm diameter SEMS should result in a longer time to RBO than an 8-mm diameter SEMS. However, the diameter of SEMS may influence the adverse event rate. Naitoh et al<sup>28</sup> retrospectively compared clinical outcomes between 8- and 10-mm diameter SEMS in SIS for UMHB. There were no significant differences between 10- and 8-mm diameter SEMS in terms of technical success (8-mm vs 10-mm group, both 100%), functional success (96% vs 100%), or early (5% vs 9%) and late (19% vs 14%) adverse event rates (other than RBO), respectively. However, the success rate of endoscopic bilateral revisionary stent insertion for RBO after SIS was significantly higher in the 10- than 8-mm diameter SEMS group (68% vs 31%;  $P = 0.044$ ). They concluded that 10-mm diameter SEMS is more suitable than 8-mm diameter SEMS from the viewpoint of endoscopic re-intervention after SIS.

#### Outcomes of stent-in-stent method

Previous studies regarding SIS with more than 20 cases are shown in Table 3.<sup>20,27,31,33,34,37–40</sup> The technical success rate was 82% to 100% and the functional success rate was 77% to 100%. The incidence of RBO was 6% to 42% and the time to RBO was 3.9 to 7.9 months. The incidence rate of adverse events other than RBO was 0% to 29%. The success rate of endoscopic re-intervention for SIS was 60% to 100%, and the success rate of endoscopic bilateral re-intervention was 30% to 83% (Table 2).<sup>14,16,20,26–29</sup>

#### Comparison of Outcomes between Stent-in-Stent and Side-by-Side

There is no consensus on whether SBS or SIS is optimal for bilateral hilar SEMS placement. Three retrospective studies compared the clinical outcomes between SIS and SBS (Table 4).<sup>16,20,41</sup> Naitoh et al<sup>20</sup> reported that there were no significant differences between SBS and SIS in terms of technical success (SBS vs SIS, 89% vs 100%), functional success (96% vs 100%), early adverse events (11% vs 4%), late complications (32% vs 8%) or incidence of RBO (20% vs 42%). The incidence of adverse events was significantly higher in SBS than SIS (44% vs 13%;  $P = 0.016$ ). The adverse events include cholecystitis and cholangitis. We hypothesized that these adverse events were associated with excessive expansion of the biliary duct and portal vein occlusion. In contrast, the time to RBO was significantly better for SBS than SIS (log-rank,  $P = 0.047$ ). There is controversy regarding whether the incidence of adverse events and time to RBO can be used to determine if SBS or SIS is optimal. Kim et al<sup>41</sup> reported that there were no significant differences between SBS and SIS in terms of functional success (SBS vs SIS, 79% vs 82%), the incidence of early adverse events (32% vs 23%) or the incidence of late adverse events (37% vs 50%). The time to RBO and survival curves did not differ significantly between SBS and SIS ( $P = 0.771$  and  $P = 0.769$ ). Law and Baron<sup>16</sup> compared SIS and SBS stenting using a Zilver biliary SEMS with a 6-Fr delivery system. They revealed that there were no significant differences with respect to the technical success

**Table 3** Previous Studies of Stent-in-Stent Methods

Author (year)	No. of patients	Technical success	Functional success	The incidence of RBO	Time to RBO (mo)	Adverse event other than RBO	Cholecystitis
Park et al <sup>31</sup> (2009)	35	94.3 (33/35)	100 (33/33)	6.1 (2/33)	5.0	0	0
Kim et al <sup>38</sup> (2009)	34	85.3 (29/34)	100 (29/29)	31.0 (9/29)	6.2	17.2 (5/29)	13.8 (4/29)
Chahal and Baron <sup>39</sup> (2010)	21	100 (21/21)	N/A	38.1 (8/21)	6.3	0	0
Hwang et al <sup>40</sup> (2011)	30	86.7 (26/30)	100 (26/26)	38.5 (10/26)	4.7	13.3 (4/30)	6.7 (2/30)
Naitoh et al <sup>20</sup> (2012)	24	100 (24/24)	100 (24/24)	41.7 (10/24)	6.0	12.5 (3/24)	4.2 (1/24)
Lee et al <sup>27</sup> (2013)	84	95.2 (80/84)	92.9 (78/84)	30.8 (24/78)	7.9	9.0 (7/78)	3.8 (3/78)
Kogure et al <sup>33</sup> (2014)	26	100 (26/26)	88.5 (23/26)	42.3 (11/26)	5.2	15.4 (4/26)	3.8 (1/26)
Kawakubo et al <sup>34</sup> (2015)	50	82.0 (41/50)	N/A	26.0 (13/50)	3.9	18.0 (9/50)	6.0 (3/50)
Park et al <sup>37</sup> (2016)	31	83.9 (26/31)	77.4 (24/31)	38.7 (12/31)	6.3	29.0 (9/31)	3.0 (1/31)

Values are presented as number only, % (number/total number), or median only.  
RBO, recurrent biliary obstruction; N/A, not applicable.

**Table 4** Previous Studies of Comparison between Side-by-Side and Stent-in-Stent

Author (year)		No. of patients	Technical success	Functional success	The incidence of RBO	Time to RBO (mo)	Adverse event other than RBO
Naitoh et al <sup>20</sup> (2012)	SBS	28	89.3 (25/28)	96.0 (24/25)	20.0 (5/25)	15.6	44.0 (11/25)
	SIS	24	100 (24/24)	100 (24/24)	41.7 (10/24)	6.0	12.5 (3/24)
	<i>P</i> -value	52	0.148	0.510	0.091	0.047*	0.016*
Kim et al <sup>41</sup> (2012)	SBS	19	N/A	78.9 (15/19)	31.6 (6/19)	3.9	21.1 (4/19)
	SIS	22	-	81.8 (18/22)	45.5 (10/22)	4.5	13.6 (3/22)
	<i>P</i> -value	41	-	1	0.557	0.074	0.831
Law and Baron <sup>16</sup> (2013)	SBS	17	81.0 (17/21)	N/A	52.9 (9/17)	N/A	N/A
	SIS	7	100 (3/3)	-	42.9 (3/7)	-	-
	<i>P</i> -value	24	1	-	0.685	-	-

Values are presented as number only, % (number/total number), or median only.  
RBO, recurrent biliary obstruction; SBS, side-by-side method; SIS, stent-in-stent method; N/A, not applicable.

\* $P < 0.05$ .

rate (SBS vs SIS, 81% vs 100%), need for re-intervention (43% vs 53%;  $P = 0.31$ ), successful re-intervention (75% vs 100%;  $P = 0.60$ ), or procedure time (63.9 minutes vs 65.5 minutes;  $P = 0.89$ ). There were no significant differences in clinical outcomes between SBS and SIS according to these three retrospective studies.

We compared the technical success rate, functional success rate, incidence of RBO, time to RBO, incidence of adverse events other than RBO and incidence of re-intervention for RBO between SIS and SBS according to previous studies. The technical success rate was similar between SBS and SIS (SBS, 73%–100%; SIS, 82%–100%), but it might have been higher in simultaneous SBS than SIS. The functional success rate was similar between SBS and SIS (SBS, 82%–100%; SIS, 77%–100%). The incidence of RBO was similar between SBS with USEMS and SIS (SBS, 3%–47%; SIS, 6%–43%), but was higher in SBS with 6-mm diameter CSEMS than SIS. The time to RBO was similar between SBS with USEMS and SIS (SBS, 4.7–15.6 months; SIS, 3.9–7.9 months), but varied widely in SBS with USEMS. The incidence rate of adverse events other than RBO was similar between SBS with USEMS and SIS (SBS, 3%–44%; SIS, 0%–29%), but varied widely in SBS with USEMS. The incidences of cholecystitis were similar between SBS and SIS (SBS, 0%–16%; SIS, 0%–15%), although we presumed it might have been higher in SBS because of excessive expansion of the biliary duct in the region of the overlapping SEMSs. The

success rate of endoscopic re-intervention was similar between SBS and SIS (SBS, 75%–100%; SIS, 60%–100%). The success rate of bilateral endoscopic re-intervention was similar between SBS and SIS (SBS, 50%–75%; SIS, 30%–67%). Inoue et al<sup>42</sup> compared the success rate of revisionary stent insertion after bilateral SEMS placement between initial SEMS using SBS or SIS, but there was no difference between SBS and SIS. According to previous studies, there were no significant differences between SBS and SIS in terms of technical success rate, functional success rate, incidence of RBO, time to RBO, incidence of adverse events other than RBO, and re-intervention for RBO. The outcomes varied widely in the previous studies because the kind and diameter of SEMS, and the devices available for these procedures, were different. Therefore, we cannot conclude whether SBS or SIS is optimal. The development of new devices and techniques for stent deployment, and further randomized controlled trials, are warranted to resolve these issues.

## Conclusions

We reviewed the current status of SBS and SIS in endoscopic bilateral SEMS placement for UMHB. No consensus has been reached on the optimal drainage area (unilateral or bilateral) for UMHB. Recent developments in devices and techniques have

allowed us to conduct endoscopic bilateral SEMS placement, although it is technically challenging. The optimal deployment method (SBS or SIS) for bilateral SEMS placement is debatable. We should be aware of features of SBS and SIS, and the techniques and devices used to conduct each method.

## Conflicts of Interest

No potential conflict of interest relevant to this article was reported.

## References

- Wagner HJ, Knyrim K, Vakil N, Klose KJ. Plastic endoprotheses versus metal stents in the palliative treatment of malignant hilar biliary obstruction. A prospective and randomized trial. *Endoscopy*. 1993;25:213-8.
- Perdue DG, Freeman ML, DiSario JA, Nelson DB, Fennerty MB, Lee JG, et al. Plastic versus self-expanding metallic stents for malignant hilar biliary obstruction: a prospective multicenter observational cohort study. *J Clin Gastroenterol*. 2008;42:1040-6.
- Sangchan A, Kongkasame W, Pugkhem A, Jenwitheesuk K, Mairiang P. Efficacy of metal and plastic stents in unresectable complex hilar cholangiocarcinoma: a randomized controlled trial. *Gastrointest Endosc*. 2012;76:93-9.
- Mukai T, Yasuda I, Nakashima M, Doi S, Iwashita T, Iwata K, et al. Metallic stents are more efficacious than plastic stents in unresectable malignant hilar biliary strictures: a randomized controlled trial. *J Hepatobiliary Pancreat Sci*. 2013;20:214-22.
- Chang WH, Kortan P, Haber GB. Outcome in patients with bifurcation tumors who undergo unilateral versus bilateral hepatic duct drainage. *Gastrointest Endosc*. 1998;47:354-62.
- De Palma GD, Galloro G, Siciliano S, Iovino P, Catanzano C. Unilateral versus bilateral endoscopic hepatic duct drainage in patients with malignant hilar biliary obstruction: results of a prospective, randomized, and controlled study. *Gastrointest Endosc*. 2001;53:547-53.
- Naitoh I, Ohara H, Nakazawa T, Ando T, Hayashi K, Okumura F, et al. Unilateral versus bilateral endoscopic metal stenting for malignant hilar biliary obstruction. *J Gastroenterol Hepatol*. 2009;24:552-7.
- Iwano H, Ryozaawa S, Ishigaki N, Taba K, Senyo M, Yoshida K, et al. Unilateral versus bilateral drainage using self-expandable metallic stent for unresectable hilar biliary obstruction. *Dig Dis Sci*. 2011;23:43-8.
- Liberato MJ, Canena JM. Endoscopic stenting for hilar cholangiocarcinoma: efficacy of unilateral and bilateral placement of plastic and metal stents in a retrospective review of 480 patients. *BMC Gastroenterology*. 2012;12:103.
- Kato H, Tsutsumi K, Kawamoto H, Okada H. Current status of endoscopic biliary drainage for unresectable malignant hilar biliary strictures. *World J Gastrointest Endosc*. 2015;7:1032-8.
- Vienne A, Hobeika E, Gouya H, Lapidus N, Fritsch J, Choury AD, et al. Prediction of drainage effectiveness during endoscopic stenting of malignant hilar strictures: the role of liver volume assessment. *Gastrointest Endosc*. 2010;72:728-35.
- Takahashi E, Fukasawa M, Sato T, Takano S, Kadokura M, Shindo H, et al. Biliary drainage strategy of unresectable malignant hilar strictures by computed tomography volumetry. *World J Gastroenterol*. 2015;21:4946-53.
- Lee TH, Kim TH, Moon JH, Lee SH, Choi HJ, Hwangbo Y, et al. Bilateral versus unilateral placement of metal stents for inoperable high-grade malignant hilar biliary strictures: a multicenter, prospective, randomized study (with video). *Gastrointest Endosc*. 2017;86:817-27.
- Lee TH, Park DH, Lee SS, Choi HJ, Lee JK, Kim TH, et al. Technical feasibility and revision efficacy of the sequential deployment of endoscopic bilateral side-by-side metal stents for malignant hilar biliary strictures: a multicenter prospective study. *Dig Dis Sci*. 2013;58:547-55.
- Chennat J, Waxman I. Initial performance profile of a new 6F self-expanding metal stent for palliation of malignant hilar biliary obstruction. *Gastrointest Endosc*. 2010;72:632-6.
- Law R, Baron TH. Bilateral metal stents for hilar biliary obstruction using a 6Fr delivery system: outcomes following bilateral and side-by-side stent deployment. *Dig Dis Sci*. 2013;58:2667-72.
- Kawakubo K, Kawakami H, Kuwatani M, Kudo T, Abe Y, Kawahata S, et al. Single-step simultaneous side-by-side placement of a self-expandable metallic stent with a 6-Fr delivery system for unresectable malignant hilar biliary obstruction: a feasibility study. *J Hepatobiliary Pancreat Sci*. 2015;22:151-5.
- Dumas R, Demuth N, Buckley M, Peten EP, Manos T, Demarquay JF, et al. Endoscopic bilateral metal stent placement for malignant hilar stenoses: identification of optimal technique. *Gastrointest Endosc*. 2000;51:334-8.
- Cheng JL, Bruno MJ, Bergman JJ, Rauws EA, Tytgat GN, Huibregtse K. Endoscopic palliation of patients with biliary obstruction caused by nonresectable hilar cholangiocarcinoma: efficacy of self-expandable metallic Wallstents. *Gastrointest Endosc*. 2002;56:33-9.
- Naitoh I, Hayashi K, Nakazawa T, Okumura F, Miyabe K, Shimizu S, et al. Side-by-side versus stent-in-stent deployment in bilateral endoscopic metal stenting for malignant hilar biliary obstruction. *Dig Dis Sci*. 2012;57:3279-85.
- Yoshida T, Hara K, Imaoka H, Hijioka S, Mizuno N, Ishihara M, et al. Benefits of side-by-side deployment of 6-mm covered self-expandable metal stents for hilar malignant biliary obstructions. *J Hepatobiliary Pancreat Sci*. 2016;23:548-55.
- Inoue T, Ishii N, Kobayashi Y, Kitano R, Sakamoto K, Ohashi T, et al. Simultaneous versus sequential side-by-side bilateral metal stent placement for malignant hilar biliary obstructions. *Dig Dis Sci*. 2017;62:2542-9.
- Kitamura K, Yamamiya A, Ishii Y, Mitsui Y, Nomoto T, Yoshida H. Side-by-side partially covered self-expandable metal stent placement for malignant hilar biliary obstruction. *Endosc Int Open*. 2017;5:E1211-7.
- Inoue T, Okumura F, Naitoh I, Fukusada S, Kachi K, Ozeki T, et al. Feasibility of the placement of a novel 6-mm diameter threaded fully covered self-expandable metal stent for malignant hilar biliary obstructions (with videos). *Gastrointest Endosc*. 2016;84:352-7.
- Kanno Y, Ito K, Koshita S, Ogawa T, Masu K, Kusunose H, et al. Soft surface irregularity of malignant perihilar biliary strictures in cholangiography as a risk factor for early dysfunction of multiple metal stents. *Dig Liver Dis*. 2017;49:1014-21.
- Fujii M, Kawamoto H, Tsutsumi K, Kato H, Hirao K, Kurihara N, et al. Management of occluded metallic stents in malignant hilar biliary stricture. *Hepatogastroenterology*. 2013;60:447-51.
- Lee TH, Moon JH, Kim JH, Park DH, Lee SS, Choi HJ, et al. Primary and revision efficacy of cross-wired metallic stents for endoscopic bilateral stent-in-stent placement in malignant hilar biliary strictures. *Endoscopy*. 2013;45:106-13.
- Naitoh I, Nakazawa T, Ban T, Okumura F, Hirano A, Takada H, et al. 8-mm versus 10-mm diameter self-expandable metallic stent in bilateral endoscopic stent-in-stent deployment for malignant hilar biliary obstruction. *J Hepatobiliary Pancreat Sci*. 2015;22:396-401.
- Hong JB, Kang DH, Nam HS, Choi CW, Kim HW, Park SB, et al. Endoscopic re-intervention for stent malfunction after stent-in-stent deployment for malignant hilar obstruction. *Medicine (Baltimore)*. 2017;96:e8867.
- Lee JH, Kang DH, Kim JY, Lee SM, Kim DH, Park CW, et al. Endoscopic bilateral metal stent placement for advanced hilar cholangiocarcinoma: a pilot study of a newly designed Y stent. *Gastrointest Endosc*. 2007;66:364-9.
- Park DH, Lee SS, Moon JH, Choi HJ, Cha SW, Kim JH, et al. Newly designed stent for endoscopic bilateral stent-in-stent placement of metallic stents in patients with malignant hilar biliary strictures: multicenter prospective feasibility study (with videos). *Gastrointest Endosc*. 2009;69:1357-60.
- Kogure H, Isayama H, Nakai Y, Tsujino T, Ito Y, Yamamoto K, et al. Newly designed large cell Niti-S stent for malignant hilar biliary obstruction: a pilot study. *Surg Endosc*. 2011;25:463-7.
- Kogure H, Isayama H, Nakai Y, Tsujino T, Matsubara S, Yashima Y, et al. High single-session success rate of endoscopic bilateral stent-in-stent placement with modified large cell Niti-S stents for malignant hilar biliary obstruction. *Dig Endosc*. 2014;26:93-9.
- Kawakubo K, Kawakami H, Toyokawa Y, Otani K, Kuwatani M, Abe Y, et al. Risk factors for technical failure of endoscopic double self-expandable metallic stent placement by partial stent-in-stent method. *J Hepatobiliary Pancreat Sci*. 2015;22:79-85.
- Lee JM, Lee SH, Chung KH, Park JM, Paik WH, Woo SM, et al. Small cell- versus large cell-sized metal stent in endoscopic bilateral stent-in-stent placement for malignant hilar biliary obstruction. *Dig Endosc*. 2015;27:692-9.
- Sugimoto M, Takagi T, Suzuki R, Konno N, Asama H, Watanabe K, et al. Predictive factors for the failure of endoscopic stent-in-stent self-expandable metallic stent placement to treat malignant hilar biliary obstruction. *World J Gastroenterol*. 2017;23:6273-80.
- Park JM, Lee SH, Chung KH, Jang DK, Ryu JK, Kim YT, et al. Endoscopic bilateral stent-in-stent placement for malignant hilar obstruction using a large cell type stent. *Hepatobiliary Pancreat Dis Int*. 2016;15:633-9.
- Kim JY, Kang DH, Kim HW, Choi CW, Kim ID, Hwang JH, et al. Usefulness of slimmer and open-cell-design stents for endoscopic bilateral stenting and endoscopic revision in patients with hilar cholangiocarcinoma (with video). *Gastrointest Endosc*. 2009;70:1109-15.
- Chahal P, Baron TH. Expandable metal stents for endoscopic bilateral stent-within-stent placement for malignant hilar biliary obstruction. *Gastrointest Endosc*. 2010;71:195-9.
- Hwang JC, Kim JH, Lim SG, Kim SS, Yoo BM, Cho SW. Y-shaped endoscopic bilateral metal stent placement for malignant hilar biliary obstruction: prospective long-term study. *Scand J Gastroenterol*. 2011;46:326-32.
- Kim KM, Lee KH, Chung YH, Shin JU, Lee JK, Lee KT, et al. A comparison of bilateral stenting methods for malignant hilar biliary obstruction. *Hepatogastroenterology*. 2012;59:341-6.
- Inoue T, Naitoh I, Okumura F, Ozeki T, Anbe K, Iwasaki H, et al. Reintervention for stent occlusion after bilateral self-expandable metallic stent placement for malignant hilar biliary obstruction. *Dig Endosc*. 2016;28:731-7.

Published by  
**Society of Gastrointestinal Intervention**





E-mail: [sgisci@sgiw.org](mailto:sgisci@sgiw.org)  
<http://www.sgiw.org>

**SGI** is a unique multidisciplinary society to encourage and facilitate clinical and scientific collaboration

between radiologists, surgeons and gastroenterologists.



## Our Goals:

-  **Multi-disciplinary Collaboration to promote world-wide Expertise**  
Establish a comprehensive GI intervention network among endoscopists, interventional radiologists and gastrointestinal surgeons for multidisciplinary collaboration and interaction
-  **Sharing and advancing technological Innovations**  
Inform, promote and globalize the many outstanding technological innovations of each of the specialties
-  **Foster future Specialists**  
Aid young brilliant doctors to make an early debut on the international stage through SGI
-  **Become a Role Model**  
Showcasing the benefits of multi-disciplinary collaboration in science, education and clinical practice